

JOINT TRAUMA SYSTEM CLINICAL PRACTICE GUIDELINE (JTS CPG)



Invasive Fungal Infection in War Wounds (CPG: 28)

Provide guidance on the recognition and comprehensive management of invasive fungal infection (IFI) in war wounds.

Contributors

CAPT Carlos J. Rodriguez, MC, USN
David R. Tribble, MD DrPH
COL Clinton K. Murray, USA, MC
CDR Elliot M. Jessie, MC, USN
Surgeon Commander Mansoor Khan, Royal Navy

CAPT Mark E. Fleming, MC, USN
LTC Benjamin K. Potter, MC, USA
Lt Col Wade T. Gordon, USAF, MC
Col Stacy A. Shackelford, USAF, MC

First Publication Date: 01 Nov 2012

Publication Date: 04 Aug 2016

Supersedes CPG dated 01 Nov 2012

TABLE OF CONTENTS

Background	2
Evaluation and Treatment	2
Diagnosis Criteria	3
Topical Treatment.....	3
Debridement and Antifungal Therapy	3
Tissue Biopsy in OR	5
OR Staff Responsibilities	5
Pathology Staff Responsibilities.....	5
Performance Improvement (PI) Monitoring.....	6
Population of Interest	6
Intent (Expected Outcomes)	6
Performance/Adherence Metrics.....	6
Data Source	7
System Reporting & Frequency	7
References	7
Appendix A: Examples of Suspicious Wounds	9
Appendix B: MD Trauma Wound Debridement OP Note	11
Appendix C: Bastion Classification of Lower Limb Injury.....	13
Appendix D: Additional Information Regarding Off-label Uses in CPGs	14

Updated Jul 2021 with the Dakin's half-strength solution.

BACKGROUND

Clinically significant infections, including invasive fungal wound infections (IFIs), have occurred in our wounded warrior patient population since the beginning of the current war in Afghanistan. During 2009-2010, a significant increase in the incidence of IFIs was observed among military personnel with wounds sustained in Afghanistan, corresponding to a greater frequency of improvised explosive device blast injuries sustained while on foot patrol in Helmand and Kandahar provinces.¹⁻³ Of particular clinical concern was an apparent association between **patient outcome and the presence of angioinvasive** molds (e.g., order Mucorales, *Aspergillus* species, and *Fusarium* species). In general, IFIs are devastating infections associated with increased mortality, morbidity (e.g., amputation), and prolonged hospitalization for survivors.^{2,4-12} In civilian literature, mortality rates have been reported as high as 38%.¹³⁻¹⁷ Among the military population, the crude mortality rate was as high as 8% during the first two years of the outbreak.⁶

Following recognition of the high number of IFI cases, the Joint Trauma System, in collaboration with the Trauma Infectious Disease Outcomes Study (TIDOS), launched an outbreak investigation. Review of the findings demonstrated that the most common mechanistic and clinical factors associated with IFI included dismounted blast injury, above knee traumatic amputations, extensive perineal/pelvic injury (observed trend, but not statistically significant), and massive packed red blood cell transfusion (≥ 20 units in the first 24 hours).^{1,2} Importantly, all IFI patients had a suspicious wound (i.e., unhealthy appearance), defined as recurrent tissue necrosis following at least two surgical debridements. (See [Appendix A: Examples of Suspicious Wounds](#).)

The morbidity associated with IFI in war wounds, which may include significant tissue loss, necessitates early treatment of patients identified as high risk. Patients frequently require surgical amputations and/or amputation revisions, which include extending to more proximal levels (e.g., transtibial to transfemoral or transfemoral to proximal transfemoral, hip disarticulation, or hemipelvectomy).¹⁸ Although prevention strategies have not been clearly identified, early and aggressive debridement of devitalized tissue and removal of debris are universally accepted as the most important interventions. The treatment of IFI is based on three main principles: debridement of infected tissue, minimization of immunosuppression (e.g., avoidance of malnutrition or excessive blood product transfusion), and utilization of empiric dual antifungal medications (e.g., amphotericin B and a broad-spectrum triazole agent) when there is a strong suspicion of an IFI.⁶ The role of topical antifungal therapy in the prevention of IFI is not clear, but topical therapies have not been demonstrated to have adverse local or systemic effects.

EVALUATION AND TREATMENT

The most important aspect of evaluation and treatment of war wounds is the recognition of unhealthy or suspicious wounds followed by early, aggressive, and repetitive surgical debridement of all devitalized tissue and organic material.

After initial debridement, **risk factors for invasive fungal infection** will be assessed. Identified risk factors include:

- Dismounted blast injury.
- Above knee immediate traumatic amputation, or progressive transition from below knee to through knee to above knee amputation.
- Extensive perineal, genitourinary, and/or rectal injury.
- Massive transfusion > 20 units packed red blood cells within 24 hours of injury.

Additionally, a web-based clinical decision support tool to assist healthcare providers in assessing the probability of developing an IFI was jointly developed by the Surgical Critical Care Initiative (SC2i) and the TIDOS project

both based at the Uniformed Services University of Health Sciences (<https://sc2i.usuhs.edu/tools-and-products>). The tool was designed for early clinical evaluation in theater as well as upon arrival at the Role 4/5 facility (Military Medical Center).

DIAGNOSIS CRITERIA

Diagnostic criteria for an IFI are: presence of a traumatic wound(s), recurrent necrosis following at least two consecutive surgical debridements, and laboratory evidence of fungal infection (i.e. mold culture positivity and/or histopathology indicating tissue invasion).^{3,6} This last criteria is usually not available at deployed Role 2 or Role 3 Military Treatment Facilities (MTFs), so clinical suspicion is key to early intervention.

TOPICAL TREATMENT

Initiate topical antifungal therapy on patients with at least three of the above risk factors.²⁰⁻²² Topical antifungal therapy should be initiated with 0.025% Dakin's. Begin with Dakin's low pressure, high volume irrigation in the operating room (OR) after the first or second operative debridement—use in lieu of saline irrigations for patients meeting criteria. Cover wounds with Dakins-soaked Kerlix dressing.²⁰⁻²³ Alternatively, an instillation vacuum dressing may be created by placing one additional infusion catheter per suction port on the vacuum dressing sponge; hold suction for 5 min and instill 50 cc 0.025% Dakin's, then clamp catheters and restart vacuum; repeat every 1-2 hours.

Half-strength Dakin's Solution²⁰⁻²³

1. 1L water, sterile or boiled
2. 5mL household bleach (5.25% hypochlorite solution, unscented)
3. Sodium bicarbonate: 1.5mL (1/2 tsp) of baking soda or 4 ampules (200mL) of 8.5% sodium bicarbonate injection (preferred, but can leave out if not available)
4. Once mixed, Dakin's solution can be stored. The half-strength solution should be diluted 1:10 with water for wound irrigation solution.

A standardized operative note for wound description to be used throughout the continuum of care for patients at increased risk for IFI is available. **Utilization of this operative note may facilitate the early detection of sequential wound necrosis** (i.e. the first sign of IFI) – [Appendix B](#). Description of Bastion Classification of lower limb injuries is presented in [Appendix C](#) and is to be documented on the first page of the Operative Note.

DEBRIDEMENT AND ANTIFUNGAL THERAPY

1. For **patients transferred to any Role 3 strategic evacuation hub**, risk factors for IFI should be assessed and ongoing resuscitation requirements should be addressed as needed. The patient should undergo surgical examination, wound washout, and debridement (if indicated) within 12-18 hours of arrival. Dakins wound irrigations or Dakins-soaked Kerlix dressings as described above should be initiated/continued.
2. **Topical antifungal treatment using 0.025% Dakin's solution via instillation vacuum dressing should be continued throughout the evacuation phase-** if possible. Flight teams should receive instruction on management of the instillation vacuum device prior to leaving the MTF. In the event of malfunction during flight, the instillation may be held while vacuum dressing is continued. The surgeon on call should be then be contacted to evaluate the dressing immediately on arrival to the next level of care.

3. **Upon arrival to the Role 4 MTF** (i.e. regional treatment facility outside of the combat zone, but prior to arrival in the United States), the patient should undergo operative exploration, wound washout, and debridement (as indicated) within 12-18 hours. Histopathology and microbiology specimens should be obtained at Role 4 on all patients with at least three risk factors for IFI and any with clinical suspicion. Topical antifungal therapy with 0.025% Dakin's solution should be continued if there is continued suspicion or three risk factors for IFI, preferably using an instillation vacuum dressing. If not available, 0.025% Dakin's soaked Kerlix dressing should be used.
4. **Upon arrival to an MTF in the United States**, the patient should undergo surgical exploration, wound washout, and debridement within 12-18 hours. Histopathology and microbiology specimens should be obtained on all patients with at least three risk factors for IFI and/or who have an unhealthy wound appearance (e.g., tissue necrosis). Topical Dakin's dressings may be discontinued at any level of care when the treating surgeon observes healthy granulation, or when histopathology and cultures are negative for fungal infection or colonization.
5. If **tissue necrosis** is observed in wounds following two consecutive debridements, not including the first two debridements in theater, **broad-spectrum antifungal and antibiotic medications should be started immediately** and Infectious Disease consultation obtained. Liposomal amphotericin B is the primary choice due to its effectiveness against mucormycosis and its reduced potential to induce nephrotoxicity.²⁴ Although voriconazole is ineffective against mucormycosis, it has shown to be an active agent against molds that are resistant to amphotericin B (e.g., *Aspergillus terreus* and *Scedosporium prolificans*).²⁵
6. In general, patients with IFI are severely injured, and are predominantly prescribed intravenous formulations of antifungal agents as there is concern for inadequate gastrointestinal antifungal absorption in the septic patient.
7. **When voriconazole is administered intravenously**, it requires a solubilizing excipient (i.e., sulfobutyl ether β -cyclodextrin), which may accumulate in patients with impaired renal function. A black box warning has been issued due to adverse effects of the accumulating solute in an animal model. Nevertheless, the effects of elevated sulfobutyl ether β -cyclodextrin are unknown in humans.²⁶ Clinical experience to date has not shown permanent renal impairment with this off-label use of voriconazole in the wounded military population.²⁷
8. Posaconazole is another triazole agent that has been found to have a 60-70% response rate as a salvage regimen against mucormycosis when prescribed orally.^{28,29} Recently, an intravenous formulation was approved and has shown to be useful.³⁰ **Dual administration of liposomal amphotericin B and a broad-spectrum triazole (i.e., clinical experience has been primarily with voriconazole) is recommended as the first-line antifungal agents as many of the wounds incurred by combat casualties grow more than one mold.**³¹ Furthermore, broad-spectrum antibiotics covering both gram-positive and gram-negative organisms (e.g., Vancomycin and Meropenem) are prescribed as fungal-infected wounds frequently have bacterial growth as well.
9. **Particular attention should be given to aggressive debridement of non-viable tissue at each debridement procedure.** The extent of necrosis and appearance of the wound before and after completion of the operation should be documented in the operative note. [Appendix B](#) shows a standardized operative note for wound description to be used for patients at increased risk for IFI. Whenever a significant amount of necrotic tissue is debrided, repeat debridement should be performed in 24 hours or less.

10. **Topical antibacterial and antifungal beads may be considered in cases of proven or strongly suspected IFI**, and may be used in conjunction with vacuum/instillation dressings. The beads should be made with liposomal amphotericin B-500 mg, voriconazole-200 mg, tobramycin-1.2 gm, and vancomycin-1 gm.

TISSUE BIOPSY IN OR

Biopsy should be done at the time of wound exploration (after initial surgical debridement) once the casualty has been evacuated from the theater of conflict (in theater if patient evacuation is delayed) and repeated on subsequent explorations if there are persistent fevers and wound necrosis raising suspicion for IFI.

1. Tissue samples should be obtained from each lower extremity in patients with bilateral lower extremity amputations. Sample all suspected areas.
2. Other sites sampled should be at the discretion of the operative surgeon.
3. At least one specimen should be taken from the junction of viable and necrotic tissue (the last piece of borderline-viable tissue removed).
4. For each site sampled, two tissue samples will be collected fresh in two separate sterile specimen containers.
 - One specimen (1 cm³) for histopathological examination
 - One specimen (1 cm³) for fungal and bacterial culture

OR STAFF RESPONSIBILITIES

The histopathology specimen must leave the OR as a fresh specimen.

1. Order histopathology and cultures (aerobic, anaerobic, and fungal). Special studies are not routinely done, but may be requested (e.g., mycobacterial and viral).
2. Clearly label specimens as “blast biopsy protocol”. Labels should also contain the following information:
 - Site (e.g., left lower extremity)
 - Patient’s name, DOB, and hospital identification number
3. Directly contact the histopathology lab during working hours and the on-call pathologist after hours and on weekends to let them know they will receive a histopathology specimen shortly. Deliver the histopathology specimen to the Pathology Lab as soon as possible.

PATHOLOGY STAFF RESPONSIBILITIES

Pathology staff will coordinate processing as rapidly as possible (≤ 24 hours).

1. Histopathological specimen will be stained with hematoxylin and eosin (H&E) and Gomori Methenamine Silver (GMS)/Periodic Acid-Schiff (PAS) stains and evaluated for fungal elements.
2. Microbiological specimen will be cultured for aerobes, anaerobes, and fungi.
3. Mycobacterial and/or viral cultures will not be done routinely under this protocol, but may be done with special request.

If **angioinvasive fungal elements or fungal elements among necrotic debris** are reported on histopathology, or if cultures are positive in the setting of recurrent necrosis, treatment with systemic antifungal medications should be initiated (or continued). **Treatment will require close consultation with Infectious Disease**; however, as a general guideline, stop systemic antifungal medications if the wound remains clean/viable for two weeks and if the patient remains clinically stable. If the patient has a fungal infection in more than one body region (e.g., extremity/pelvis, abdomen, and chest), long-term treatment may be indicated.

NOTE:

1. Fungus can take up to six weeks to grow in culture medium. Therefore, it is **recommended that the cultures be checked frequently for two weeks**; then once a week for four additional weeks before they are considered final. In addition, wounds without recurrent tissue necrosis may have mold colonization and not a true infection.³²
2. Initial studies have shown that combat IFI wound cultures growing order Mucorales will have a second non-Mucorales fungus present 30% of the time. *Aspergillus* species is more difficult to grow than order Mucorales, but should be suspected and empirically treated initially as it has been shown to be virulent in this patient population.³¹ Therefore, dual use of a broad-spectrum triazole and liposomal amphotericin B is suggested for wounds infected with either or both of these fungi. If long-term treatment is required, the antifungal medications should be targeted based on culture results.

As aggressive surgical debridement of all necrotic and infected tissue remains the mainstay of treatment for IFI, surgical exploration and debridement should continue at least every 24 hours until cessation of necrosis occurs. Wound coverage and closure should not occur until after the wound is clean, contracting, and granulating.

PERFORMANCE IMPROVEMENT (PI) MONITORING

POPULATION OF INTEREST

Patients at with 3 or more risk factors for invasive fungal infection (dismounted blast, above knee amputation, perineal genitourinary or rectal injury, MT> 20 units RBC + WB within 24h of injury.)

INTENT (EXPECTED OUTCOMES)

1. Patients with ≥ 3 IFI risk factors undergo surgical debridement in the OR within 12-18 hours of arrival at Role 3 or 4 MTFs.
2. Patients with ≥ 3 IFI risk factors have Dakin's solution applied to the wounds starting at the first or second debridement.
3. An operative note for wound debridement includes the extent of necrosis quantified as a percentage of each wound.

PERFORMANCE/ADHERENCE METRICS

1. Number and percentage of patients in the population of interest who undergo surgical debridement in the OR within 12-18 hours of arrival at Role 3 or 4 MTFs.
2. Number and percentage of patients in the population of interest who have Dakin's solution applied to the wounds starting at the first or second debridement.
3. Number and percentage of patients in the population of interest who have an operative note that quantifies the extent of wound necrosis as a percentage of each wound.

DATA SOURCE

- Patient Record
- Department of Defense Trauma Registry (DoDTR)

SYSTEM REPORTING & FREQUENCY

The above constitutes the minimum criteria for PI monitoring of this CPG. System reporting will be performed annually; additional PI monitoring and system reporting may be performed as needed.

The system review and data analysis will be performed by the JTS Chief and the JTS PI Branch.

REFERENCES

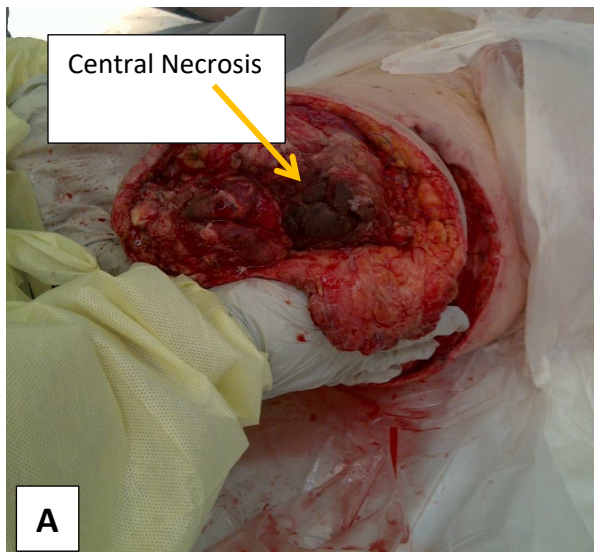
1. Trauma Infectious Diseases Outcomes Study Group: Department of Defense Technical Report - Invasive Fungal Infection Case Investigation. Bethesda, MD: Infectious Disease Clinical Research Program, Uniformed Services University of the Health Sciences; April 11, 2011. [not publically available].
2. Warkentien T, Rodriguez C, Lloyd B, Wells J, Weintrob A, Dunne J, et al. Invasive mold infections following combat-related injuries. Clin Infect Dis 2012; 55(11): 1441-49.
3. Weintrob AC, Weisbrod AB, Dunne JR, Rodriguez CJ, Malone D, Lloyd BA, et al. Combat trauma-associated invasive fungal wound infections: epidemiology and clinical classification. Epidemiol Infect 2015; 143(1): 214-24.
4. Paolino KM, Henry JA, Hospenthal DR, Wortmann GW, Hartzell JD. Invasive fungal infections following combat-related injury. Mil Med 2012; 177(6): 681-5.
5. Evriviades D, Jeffery S, Cubison T, Lawton G, Gill M, Mortiboy D. Shaping the military wound: issues surrounding the reconstruction of injured servicemen at the Royal Centre for Defence Medicine. Philos Trans R Soc Lond B Biol Sci 2011; 366(1562): 219-30.
6. Tribble DR, Rodriguez CJ. Combat-related invasive fungal wound infections. Curr Fungal Infect Rep 2014; 8(4): 277-86.
7. Fares Y, El-Zaatari M, Fares J, Bedrosian N, Yared N. Trauma-related infections due to cluster munitions. J Infect Public Health 2013; 6(6): 482-86.
8. Lundy JB, Driscoll IR. Experience with proctectomy to manage combat casualties sustaining catastrophic perineal blast injury complicated by invasive mucor soft-tissue infections. Mil Med 2014; 179(3): e347-50.
9. Tully CC, Romanelli AM, Sutton DA, Wickes BL, Hospenthal DR. Fatal Actinomyces elegans var. kuwaitiensis infection following combat trauma. J Clin Microbiol 2009; 47(10): 3394-9.
10. Radowsky JS, Strawn AA, Sherwood J, Braden A, Liston W. Invasive mucormycosis and aspergillosis in a healthy 22-year-old battle casualty: case report. Surg Infect (Larchmt) 2011; 12(5): 397-400.
11. Mitchell TA, Hardin MO, Murray CK, et al. Mucormycosis attributed mortality: a seven-year review of surgical and medical management. Burns 2014; 40(8): 1689-95.
12. Hospenthal DR, Chung KK, Laret K, et al. Saksenea erythrospora infection following combat trauma. J Clin Microbiol 2011; 49(10): 3707-9.
13. Vitrat-Hincky V, Lebeau B, Bozonnet E, et al. Severe filamentous fungal infections after widespread tissue damage due to traumatic injury: six cases and review of the literature. Scand J Infect Dis 2009; 41(6-7): 491-500.
14. Hajdu S, Obradovic A, Presterl E, Vecsei V. Invasive mycoses following trauma. Injury 2009; 40(5): 548-54.

15. Roden MM, Zaoutis TE, Buchanan WL, Knudsen TA, Sarkisova TA, Schaufele RL, et al. Epidemiology and outcome of zygomycosis: a review of 929 reported cases. *Clin Infect Dis* 2005; 41(5): 634-53.
16. Neblett Fanfair R, Benedict K, Bos J, et al. Necrotizing cutaneous mucormycosis after a tornado in Joplin, Missouri, in 2011. *N Engl J Med* 2012; 367(23): 2214-25.
17. Ribes JA, Vanover-Sams CL, Baker DJ. Zygomycetes in human disease. *Clin Microbiol Rev* 2000; 13(2): 236-301.
18. Lewandowski LR: (2014). Early Complications and outcomes in combat injury related invasive fungal wound infections: a case-control analysis. Presentation to Society of Military Orthopaedic Surgeons 56th Annual Meeting. Scottsdale, AZ.
19. Rodriguez C, Weintrob AC, Shah J, Malone D, Dunne JR, Weisbrod AB, et al. Risk factors associated with invasive fungal Infections in combat trauma. *Surg Infect (Larchmt)* 2014; 15(5): 521-26.
20. Lewandowski L, Purcell R, Fleming M, Gordon WT. The use of dilute Dakin's solution for the treatment of angioinvasive fungal infection in the combat wounded: a case series. *Mil Med* 2013; 178(4): e503-07.
21. Barsoumian A, Sanchez CJ, Mende K, Tully CC, Beckius ML, Akers KS, et al. In vitro toxicity and activity of Dakin's solution, mafenide acetate, and amphotericin B on filamentous fungi and human cells. *J Orthop Trauma* 2013; 27(8): 428-36.
22. Vick LR, Propst RC, Bozeman R, Wysocki AB. Effect of Dakin's solution on components of a dermal equivalent. *J Surg Res* 2009; 155(1): 54-64.
23. Kheirabadi BS, Mace JE, Terrazas IB, et al. Safety evaluation of new hemostatic agents, smectite granules, and kaolin-coated gauze in a vascular injury wound model in swine. *J Trauma* 2010; 68(2): 269-78.
24. Spellberg B, Walsh TJ, Kontoyiannis DP, Edwards J, Jr., Ibrahim AS. Recent advances in the management of mucormycosis: from bench to bedside. *Clin Infect Dis* 2009; 48(12): 1743-51.
25. Meletiadis J, Antachopoulos C, Stergiopoulou T, et al. Differential fungicidal activities of amphotericin B and voriconazole against *Aspergillus* species determined by microbroth methodology. *Antimicrob Agents Chemother* 2007; 51(9): 3329-37.
26. Luke DR, Tomaszewski K, Damle B, Schlamm HT. Review of the basic and clinical pharmacology of sulfobutylether-beta-cyclodextrin (SBECD). *J Pharm Sci* 2010; 99(8): 3291-301.
27. Malone D, Rodriguez C, Dunne J, Wells J, Fleming M, Warkentien T et al: (2012). Trials and tribulations; the expedited development of an IFI CPG. Presentation to the Surgical Infection Society 32nd Annual Meeting. Dallas, TX.
28. Greenberg RN, Mullane K, van Burik JA, et al. Posaconazole as salvage therapy for zygomycosis. *Antimicrob Agents Chemother* 2006; 50(1): 126-33.
29. van Burik JA, Hare RS, Solomon HF, Corrado ML, Kontoyiannis DP. Posaconazole is effective as salvage therapy in zygomycosis: a retrospective summary of 91 cases. *Clin Infect Dis* 2006; 42(7): e61-5.
30. Moore JN, Healy JR, Kraft WK. Pharmacologic and clinical evaluation of posaconazole. *Expert Rev Clin Pharmacol* 2015; 8(3): 321-34.
31. Warkentien TE, Shaikh F, Weintrob AC, Rodriguez CJ, Murray CK, Lloyd BA, et al. Impact of Mucorales and other invasive molds on clinical outcomes of polymicrobial traumatic wound infections. *J Clin Microbiol* 2015; 53(7): 2262-70.
32. Rodriguez CJ, Weintrob AC, Dunne JR, et al. Clinical relevance of mold culture positivity with and without recurrent wound necrosis following combat-related injuries. *J Trauma Acute Care Surg* 2014; 77(5): 769-73.
33. Jacobs N, Rourke K, Rutherford J, Hicks A, Smith SR, Templeton P, et al. Lower limb injuries caused by improvised explosive devices: proposed 'Bastion classification' and prospective validation. *Injury* 2014; 45(9): 1422-28.

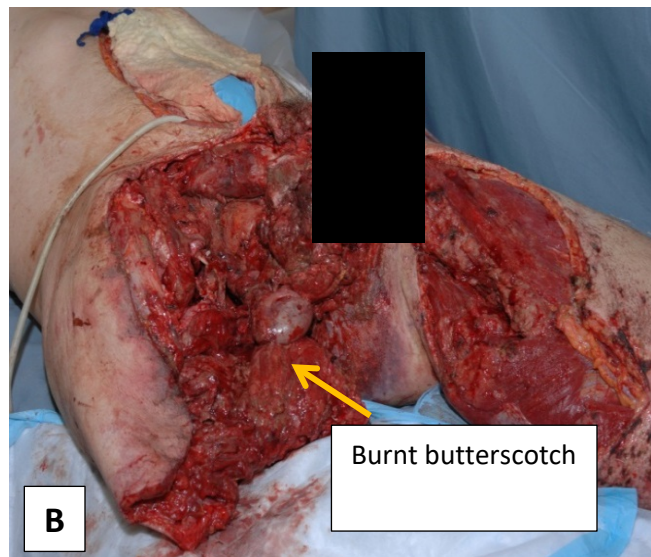
APPENDIX A: EXAMPLES OF SUSPICIOUS WOUNDS

All photos are from different patients.

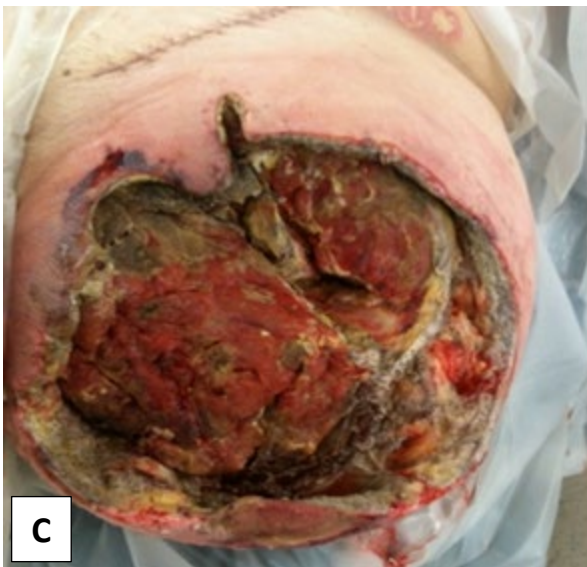(A) Patient is 8 days out from injury. His wound is showing central necrosis. Debridement day prior revealed healthy appearing, bleeding tissue.



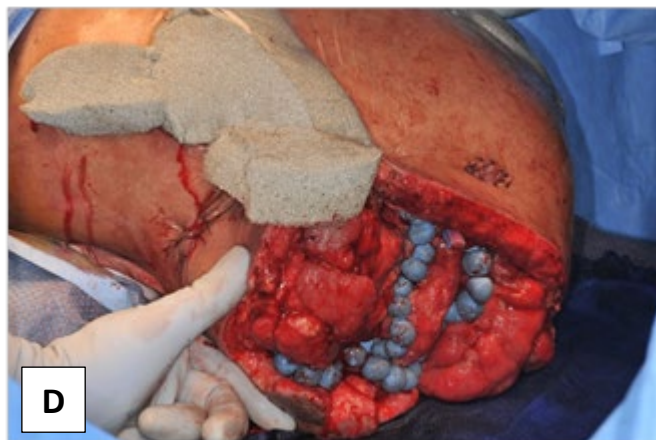
(B) Patient is also 8 days out from injury. Patchy necrosis is seen throughout his right-sided hemipelvectomy. Upon closer inspection, one notices a 'burnt butterscotch' appearance overlying tissue. Anecdotally, this is an additional IFI clinical indicator.



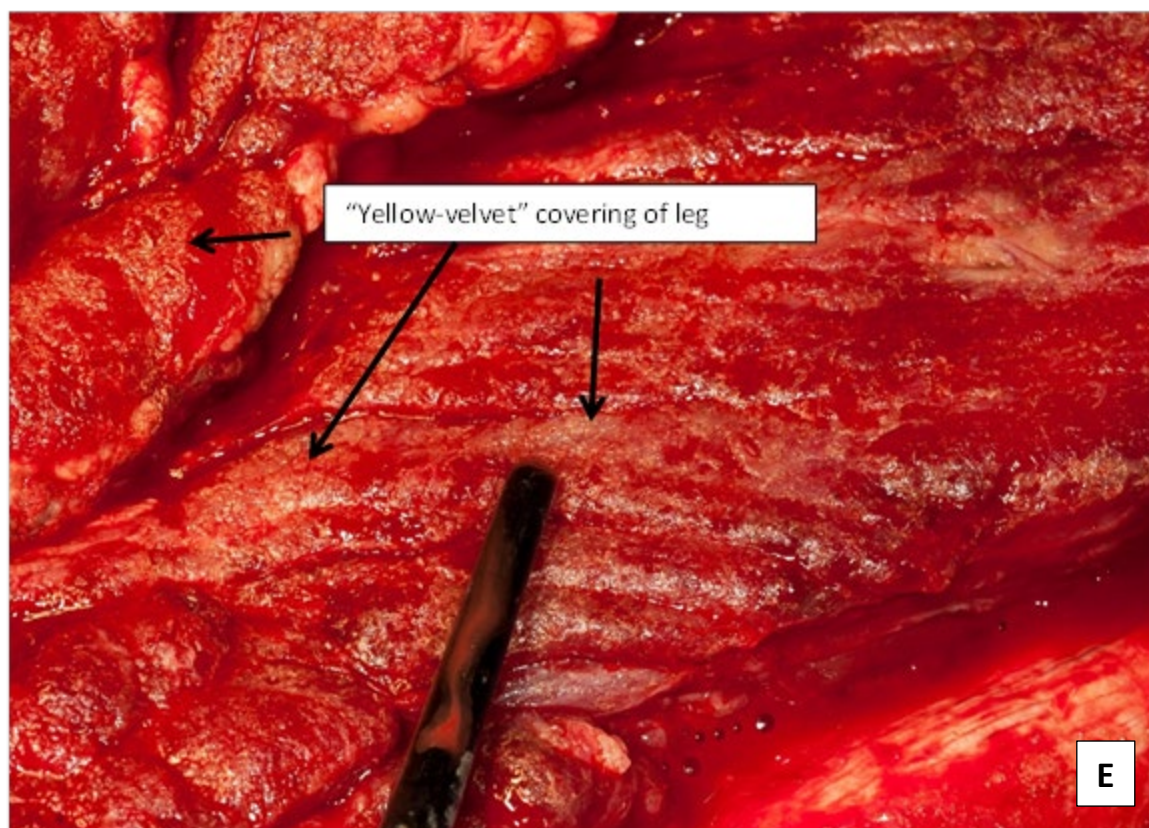
(C) Provides example of tissue necrosis in a previously healthy-appearing wound bed.



(D) Patient is recovering well, but still being treated with anti-microbial beads



(E) Looking closely at the wound, one can see a 'yellow-velvet' covering to the wound. This is indicative of an *Aspergillus* infection.



APPENDIX B: MD TRAUMA WOUND DEBRIDEMENT OP NOTE

MD TRAUMA WOUND DEBRIDEMENT OP NOTE	
Date of Operation:	
Pre-Operative Diagnosis:	
Post-Operative Diagnosis:	
Initial Bastion Amputation Class:	1 (foot) 2 (below knee) 3 (above knee) 4 (proximal thigh) 5 (involves buttock/perineum)
Surgeon(s):	
Anesthesia:	
EBL:	
Fluids/Blood Products Administered:	
OPERATIVE SITE #1: (specify)	
Procedure <input type="checkbox"/> Initial amputation (level) _____ <input type="checkbox"/> Revision amputation (level) _____ <input type="checkbox"/> Debridement/Washout Number _____ <input type="checkbox"/> DPC <input type="checkbox"/> Exam/Dressing change under Anesthesia <input type="checkbox"/> Ex-Fix (initial) <input type="checkbox"/> Ex-Fix (revision) <input type="checkbox"/> ORIF <input type="checkbox"/> Orthopedic hardware removal <input type="checkbox"/> Other _____	Wound Description Total size of wound: _____ cm ² <input type="checkbox"/> Clean <input type="checkbox"/> Approx 25% necrotic <input type="checkbox"/> Approx 50% necrotic <input type="checkbox"/> Approx 75% necrotic <input type="checkbox"/> Completely necrotic <input type="checkbox"/> Grossly purulent <input type="checkbox"/> Gross mold
Samples Sent <input type="checkbox"/> None <input type="checkbox"/> Aerobic culture <input type="checkbox"/> Anaerobic culture <input type="checkbox"/> Fungal culture <input type="checkbox"/> Histopathology <input type="checkbox"/> Other _____	Adjunctive Therapy <input type="checkbox"/> Antimicrobial beads (type) _____ <input type="checkbox"/> Dakin's soaked dressings <input type="checkbox"/> Dakin's Instill Device (started) <input type="checkbox"/> Dakin's Instill Device (Renewed) <input type="checkbox"/> Negative pressure therapy <input type="checkbox"/> Other _____
Comments:	

MD TRAUMA WOUND DEBRIDEMENT OP NOTE	
OPERATIVE SITE #2: (specify)	
Procedure <input type="checkbox"/> Initial amputation (level) _____ <input type="checkbox"/> Revision amputation (level) _____ <input type="checkbox"/> Debridement/Washout Number _____ <input type="checkbox"/> DPC <input type="checkbox"/> Exam/Dressing change under Anesthesia <input type="checkbox"/> Ex-Fix (initial) <input type="checkbox"/> Ex-Fix (revision) <input type="checkbox"/> ORIF <input type="checkbox"/> Orthopedic hardware removal <input type="checkbox"/> Other _____	Wound Description Total size of wound: _____ cm ² <input type="checkbox"/> Clean <input type="checkbox"/> Approx 25% necrotic <input type="checkbox"/> Approx 50% necrotic <input type="checkbox"/> Approx 75% necrotic <input type="checkbox"/> Completely necrotic <input type="checkbox"/> Grossly purulent <input type="checkbox"/> Gross mold
Samples Sent <input type="checkbox"/> None <input type="checkbox"/> Aerobic culture <input type="checkbox"/> Anaerobic culture <input type="checkbox"/> Fungal culture <input type="checkbox"/> Histopathology <input type="checkbox"/> Other _____	Adjunctive Therapy <input type="checkbox"/> Antimicrobial beads (type) _____ <input type="checkbox"/> Dakin's soaked dressings <input type="checkbox"/> Dakin's Instill Device (started) <input type="checkbox"/> Dakin's Instill Device (Renewed) <input type="checkbox"/> Negative pressure therapy <input type="checkbox"/> Other _____
Comments:	
OPERATIVE SITE #3: (specify)	
Procedure <input type="checkbox"/> Initial amputation (level) _____ <input type="checkbox"/> Revision amputation (level) _____ <input type="checkbox"/> Debridement/Washout Number _____ <input type="checkbox"/> DPC <input type="checkbox"/> Exam/Dressing change under Anesthesia <input type="checkbox"/> Ex-Fix (initial) <input type="checkbox"/> Ex-Fix (revision) <input type="checkbox"/> ORIF <input type="checkbox"/> Orthopedic hardware removal <input type="checkbox"/> Other _____	Wound Description Total size of wound: _____ cm ² <input type="checkbox"/> Clean <input type="checkbox"/> Approx 25% necrotic <input type="checkbox"/> Approx 50% necrotic <input type="checkbox"/> Approx 75% necrotic <input type="checkbox"/> Completely necrotic <input type="checkbox"/> Grossly purulent <input type="checkbox"/> Gross mold
Samples Sent <input type="checkbox"/> None <input type="checkbox"/> Aerobic culture <input type="checkbox"/> Anaerobic culture <input type="checkbox"/> Fungal culture <input type="checkbox"/> Histopathology <input type="checkbox"/> Other _____	Adjunctive Therapy <input type="checkbox"/> Antimicrobial beads (type) _____ <input type="checkbox"/> Dakin's soaked dressings <input type="checkbox"/> Dakin's Instill Device (started) <input type="checkbox"/> Dakin's Instill Device (Renewed) <input type="checkbox"/> Negative pressure therapy <input type="checkbox"/> Other _____
Comments:	

APPENDIX C: BASTION CLASSIFICATION OF LOWER LIMB INJURY

BASTION CLASSIFICATION OF LOWER LIMB INJURY CAUSED BY IED. THE MOST PROXIMAL EXTENT.	
Class of limb injury	Description
1	Injury confined to foot
2	Injury involving lower leg permitting effective below-knee tourniquet application
3	Injury involving proximal lower leg or thigh, permitting effective above-knee tourniquet application
4	Proximal thigh injury, preventing effective tourniquet application
5	Any injury with buttock involvement

APPENDIX D: ADDITIONAL INFORMATION REGARDING OFF-LABEL USES IN CPGS

PURPOSE

The purpose of this Appendix is to ensure an understanding of DoD policy and practice regarding inclusion in CPGs of “off-label” uses of U.S. Food and Drug Administration (FDA)–approved products. This applies to off-label uses with patients who are armed forces members.

BACKGROUND

Unapproved (i.e. “off-label”) uses of FDA-approved products are extremely common in American medicine and are usually not subject to any special regulations. However, under Federal law, in some circumstances, unapproved uses of approved drugs are subject to FDA regulations governing “investigational new drugs.” These circumstances include such uses as part of clinical trials, and in the military context, command required, unapproved uses. Some command requested unapproved uses may also be subject to special regulations.

ADDITIONAL INFORMATION REGARDING OFF-LABEL USES IN CPGS

The inclusion in CPGs of off-label uses is not a clinical trial, nor is it a command request or requirement. Further, it does not imply that the Military Health System requires that use by DoD health care practitioners or considers it to be the “standard of care.” Rather, the inclusion in CPGs of off-label uses is to inform the clinical judgment of the responsible health care practitioner by providing information regarding potential risks and benefits of treatment alternatives. The decision is for the clinical judgment of the responsible health care practitioner within the practitioner-patient relationship.

ADDITIONAL PROCEDURES**Balanced Discussion**

Consistent with this purpose, CPG discussions of off-label uses specifically state that they are uses not approved by the FDA. Further, such discussions are balanced in the presentation of appropriate clinical study data, including any such data that suggest caution in the use of the product and specifically including any FDA-issued warnings.

Quality Assurance Monitoring

With respect to such off-label uses, DoD procedure is to maintain a regular system of quality assurance monitoring of outcomes and known potential adverse events. For this reason, the importance of accurate clinical records is underscored.

Information to Patients

Good clinical practice includes the provision of appropriate information to patients. Each CPG discussing an unusual off-label use will address the issue of information to patients. When practicable, consideration will be given to including in an appendix an appropriate information sheet for distribution to patients, whether before or after use of the product. Information to patients should address in plain language: a) that the use is not approved by the FDA; b) the reasons why a DoD health care practitioner would decide to use the product for this purpose; and c) the potential risks associated with such use.