

# Joint Theater Trauma System Clinical Practice Guideline

---

## INITIAL CARE OF OCULAR AND ADNEXAL INJURIES BY NON-OPHTHALMOLOGISTS

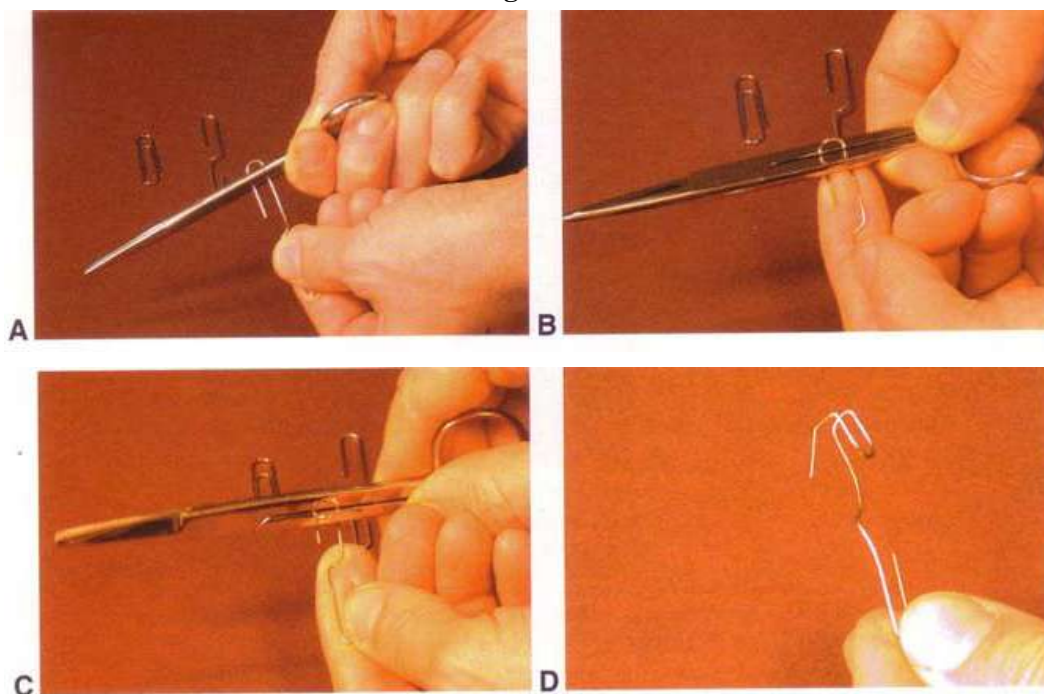
Original Release/Approval	1 Aug 2007	Note: This CPG requires an annual review.	
Reviewed:	Jan 2011	Approved:	6 Mar 12
Supersedes:	Recommendations for Initial Care of Ocular and Adnexal Injuries at Level I and II Facilities		
<input type="checkbox"/> Minor Changes (or)	<input type="checkbox"/> Changes are substantial and require a thorough reading of this CPG (or)		
<input checked="" type="checkbox"/> Significant Changes:	PI monitoring plan added		

1. **Goal.** To provide a step-by-step approach for the non-ophthalmologist in the care and treatment of ocular and adnexal injuries sustained in the combat theater.
2. **Background.** Despite comprising only 0.1% of the total body surface area, ocular and adnexal injuries are found in 5-10% of all combat casualties. Advances in both ballistic eyewear and acute ophthalmic surgical care have dramatically reduced the incidence of severe vision loss or loss of the eye associated with these injuries.
3. **Evaluation and Treatment.**
  - a. Obtain a detailed history – specifically addressing whether ballistic eyewear was being worn correctly at the time of injury – and check visual acuity and compare to uninjured side.
  - b. Inspect eyes and adnexal structures using bent paper clips, if necessary, to elevate the upper eyelid **without placing pressure, either directly or indirectly, on the globe to assess for a ruptured globe.** (See Figure 1 below on how to make an eyelid retractor from a paperclip.)

---

Guideline Only/Not a Substitute for Clinical Judgment  
March 2012

**Figure 1**



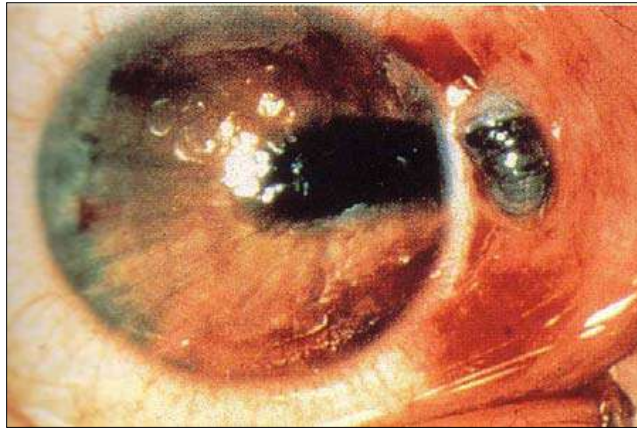
- c. Superficial conjunctival or corneal foreign bodies may be irrigated away or removed with a moistened sterile swab under topical anesthesia. Apply ophthalmic antibiotic ointment.
- d. **DO NOT remove impaled foreign bodies.**
- e. Treat corneal abrasions with ophthalmic antibiotic ointment. Avoid patching.
- f. Identify ruptured or lacerated eyeball by prolapse of intraocular tissues (such as iris or lens) through a wound (Figure 2), hemorrhagic swelling of conjunctiva (Figure 3), positive Seidel sign (Figure 4) on the cornea, hyphema (blood in the anterior chamber), a very shallow or abnormally deep anterior chamber (compared to uninjured eye), a peaked pupil (Figure 2), decreased extraocular motility, or severe vision loss. **Do not apply pressure to the eye. Ask the patient not to strain or squeeze their eyelids. Tape a metal Fox shield over the eye or use the bottom cut out of a paper cup (Figure 5) if a Fox shield is not available. Do not apply a dressing or patch to an open globe. Do not use ointment on an open globe. Avoid interventions that induce nausea/vomiting.** Start Fluoroquinolone antibiotic PO or IV (Ciprofloxacin 500 mg BID and begin an anti-emetic (Phenergan 50 mg or Compazine 10 mg IM/IV). Evacuate to an Ophthalmologist.

## Joint Theater Trauma System Clinical Practice Guideline

---

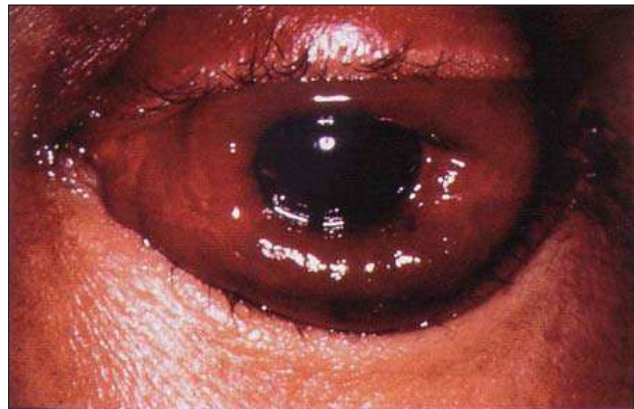- g. Uveal prolapse out a scleral wound. **The pupil is peaked toward the site of the rupture with some hemorrhagic chemosis** (Figure 2).

**Figure 2**



- h. Hemorrhagic swelling of the conjunctiva or hemorrhagic chemosis is an ominous sign of a possible open globe (Figure 3).

**Figure 3**

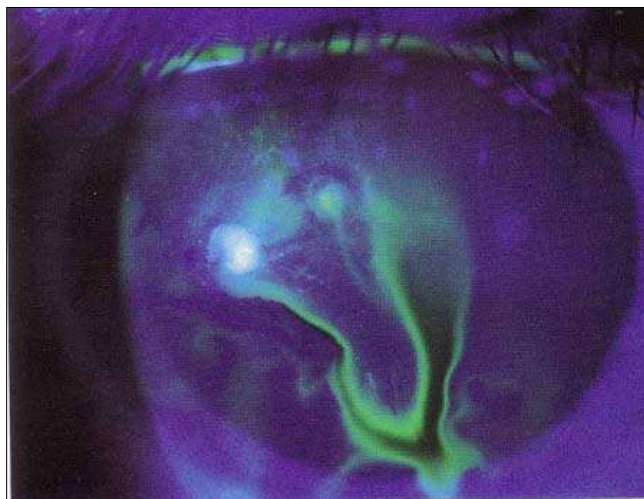


## Joint Theater Trauma System Clinical Practice Guideline

---

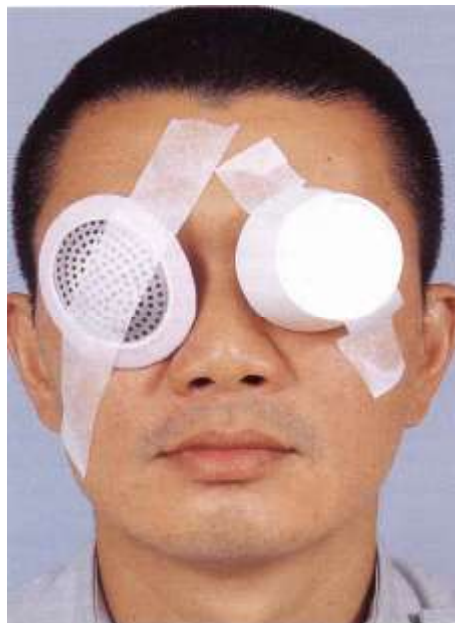- i. A moistened fluorescein strip applied to the cornea can reveal aqueous flowing from a corneal wound by allowing one to visualize the flow of **aqueous fluid out of the eye** (Figure 4).

**Figure 4**



- j. Protect an open globe with a metal shield or the bottom of a paper cup without an underlying dressing (Figure 5).

**Figure 5**

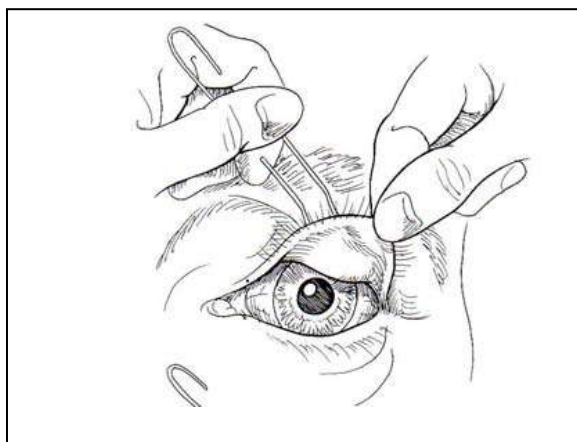


## Joint Theater Trauma System Clinical Practice Guideline

---

- k. Anyone with possible intraocular foreign bodies – history of metal on metal strike, explosives, shrapnel, high velocity projectiles, etc., associated with eye injury, should be treated as one with a penetrating eye injury and evacuated to a Level III Ophthalmologist. If there is concern for an eye injury the patient should be transferred to a facility that has an ophthalmologist. Fox eye shields should be placed and there should be minimal manipulation of the eye in question. The use of ocular ultrasound should not be performed routinely in theatre and if it is, it should only be performed by a qualified ophthalmologist.
- l. **NEVER provide topical anesthetics such as tetracaine or proparacaine for self medication.** Avoid prescribing topical corticosteroids.
- m. For chemical burns, irrigate for 60 minutes while removing any particles from the eye. You must flip the upper eyelid (Figure 6) and inspect the inferior fornix to evaluate for hidden **alkaline or acidic debris**.
- n. Flip the upper eyelid by firmly holding the eyelashes and lifting up while pressing down on the middle of the eyelid at the border of the tarsus with a paperclip or the shaft of cotton tipped applicator (Figure 6).

**Figure 6**



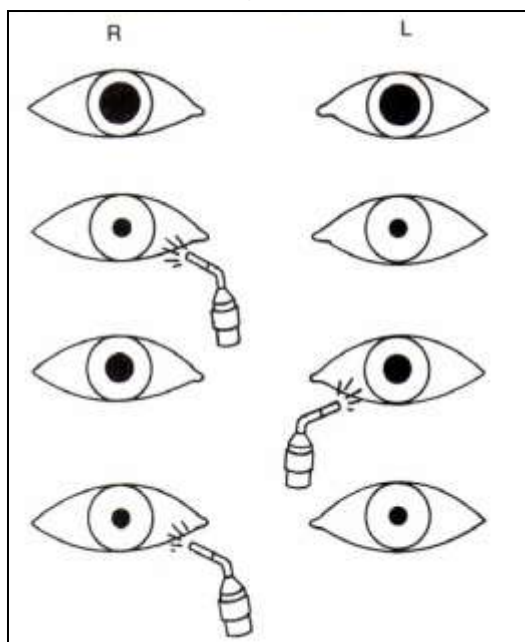
- o. For severe injuries provide tetanus prophylaxis and begin systemic antibiotics (Fluroquinolone).
- p. If you suspect orbital compartment syndrome from intraorbital bleeding – gross proptosis, tense tissues that are resistant to retropulsion (direct pressure), decreased vision, color vision loss, and Marcus Gunn pupil or afferent papillary defect – perform lateral canthotomy and cantholysis (see the *Emergency War Surgery Handbook* for specific details).

## Joint Theater Trauma System Clinical Practice Guideline

---

- q. A Marcus Gunn pupil or afferent pupillary defect is a sign of severe optic nerve dysfunction. An example of this is demonstrated in Figure 7. The pupils are dilated in the dark. A bright light shone in an eye with a normal optic nerve will cause pupillary constriction of BOTH eyes. If one then swings the light quickly to the eye with optic nerve dysfunction both pupils will then dilate. Swinging the light back to the good eye causes constriction of both pupils again. This indicates that there is a left afferent pupillary defect (Figure 7).

**Figure 7**



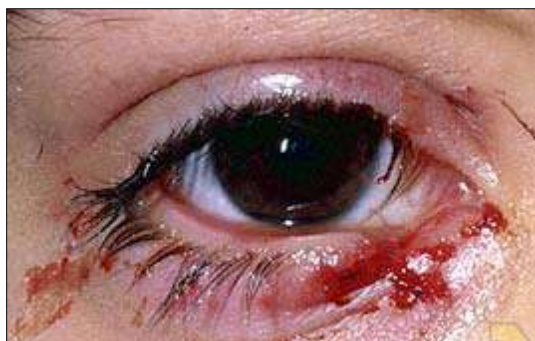- r. Patients with orbital floor fractures (blunt trauma with decreased extraocular motility, especially in vertical gaze and numbness on cheek) should be told not to hold in sneezes and not to blow their nose. May give systemic antibiotics and send for evaluation by Ophthalmology, ENT, or OMFS.
- s. Only repair eyelid lacerations that: (1) do not involve the eyelid margin; and (2) are without fat prolapsing through the wound. After thoroughly irrigating the wounds they should be closed with 6-0 suture.
- t. Eyelid lacerations that involve the margin or are deep with fat prolapse should be evacuated to a Level III Ophthalmologist with a moist dressing applied.

## Joint Theater Trauma System Clinical Practice Guideline

---

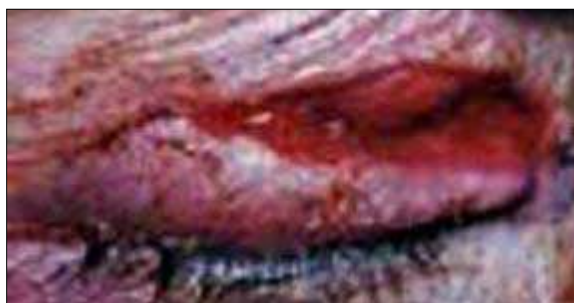- u. Laceration involving the margin of eyelid should be repaired by an Ophthalmologist (Figure 8).

**Figure 8**



- v. Deep eyelid laceration that should be explored by an Ophthalmologist (Figure 9).

**Figure 9**



- w. If there is eyelid tissue that is amputated or partially amputated, DO NOT discard. Wrap in moist gauze and send with patient.
- x. Evacuate any patient with severe visual acuity loss after an injury to an Ophthalmologist as soon as possible.
- y. If the cornea is exposed because of eyelid tissue avulsion, or retraction of eyelids due to burns, apply ophthalmic antibiotic ointment, protect the cornea and eye by applying a Fox Shield and evacuate the patient to a Level III Ophthalmologist.

#### **4. Performance Improvement (PI) Monitoring.**

- a. Intent (Expected Outcomes).
  - 1) All patients will have a basic eye and vision exam on admission which will be documented on the Trauma Flow Sheet or elsewhere in the medical record.
  - 2) Fox shields or like devices are utilized in all cases of suspected or know globe injury.
  - 3) Fox shields or like devices are applied correctly so there is no pressure on the globe and no dressings are placed between the shield and the eye.
  - 4) All patients are referred to an Ophthalmologist in theater for known or suspected globe injuries.

---

Guideline Only/Not a Substitute for Clinical Judgment  
March 2012

## Joint Theater Trauma System Clinical Practice Guideline

---

5) Instrumentation of known or suspected globe injuries is performed exclusively by an Ophthalmologist.

b. Performance/Adherence Measures.

- 1) All patients received basic eye and vision exams during initial evaluation and results were documented on the trauma flow sheet or elsewhere in the medical record.
- 2) Fox shield (or appropriate substitute) was placed over the eye and against the bony prominences around the eye when known or suspected globe trauma and/or injury existed.
- 3) Fox shield (or appropriate substitute) was applied appropriately over the eye with no dressings placed between the shield and the eye.
- 4) All patients with known or suspected globe injuries were referred to an Ophthalmologist in theater.
- 5) Instrumentation of known or suspected globe injuries was performed by an Ophthalmologist.

c. Data Source.

- 1) Patient Record
- 2) Joint Theater Trauma Registry (JTTR)
- 3) Trauma Flow Sheet

d. System Reporting & Frequency. The above constitutes the minimum criteria for PI monitoring of this CPG. System reporting will be performed annually; additional PI monitoring and system reporting may be performed as needed.

The system review and data analysis will be performed by the Joint Theater Trauma System (JTTS) Director, JTTS Program Manager, and the Joint Trauma System (JTS) Performance Improvement Branch.

**5. Responsibilities.** It is the trauma team leader's responsibility to ensure familiarity, appropriate compliance and PI monitoring at the local level with this CPG.

**6. References.**

- <sup>1</sup> BSCS series published by the American Academy of Ophthalmology
- <sup>2</sup> Ophthalmic Care of the Combat Casualty
- <sup>3</sup> Neuro-Ophthalmology by Frank J. Bajandas
- <sup>4</sup> <http://www.kellogg.umich.edu/theeyeshaveit/trauma/images/laceration-lid.jpg>

Approved by CENTCOM JTTS Director, JTS Director and  
CENTCOM SG

Opinions, interpretations, conclusions, and recommendations are those of the authors and are not necessarily endorsed by the Services or DoD.
---

---

Guideline Only/Not a Substitute for Clinical Judgment  
March 2012



## APPENDIX A

### ADDITIONAL INFORMATION REGARDING OFF-LABEL USES IN CPGs

#### 1. Purpose.

The purpose of this Appendix is to ensure an understanding of DoD policy and practice regarding inclusion in CPGs of “off-label” uses of U.S. Food and Drug Administration (FDA)–approved products. This applies to off-label uses with patients who are armed forces members.

#### 2. Background.

Unapproved (i.e., “off-label”) uses of FDA-approved products are extremely common in American medicine and are usually not subject to any special regulations. However, under Federal law, in some circumstances, unapproved uses of approved drugs are subject to FDA regulations governing “investigational new drugs.” These circumstances include such uses as part of clinical trials, and in the military context, command required, unapproved uses. Some command requested unapproved uses may also be subject to special regulations.

#### 3. Additional Information Regarding Off-Label Uses in CPGs.

The inclusion in CPGs of off-label uses is not a clinical trial, nor is it a command request or requirement. Further, it does not imply that the Military Health System requires that use by DoD health care practitioners or considers it to be the “standard of care.” Rather, the inclusion in CPGs of off-label uses is to inform the clinical judgment of the responsible health care practitioner by providing information regarding potential risks and benefits of treatment alternatives. The decision is for the clinical judgment of the responsible health care practitioner within the practitioner-patient relationship.

#### 4. Additional Procedures.

- a. Balanced Discussion. Consistent with this purpose, CPG discussions of off-label uses specifically state that they are uses not approved by the FDA. Further, such discussions are balanced in the presentation of appropriate clinical study data, including any such data that suggest caution in the use of the product and specifically including any FDA-issued warnings.
- b. Quality Assurance Monitoring. With respect to such off-label uses, DoD procedure is to maintain a regular system of quality assurance monitoring of outcomes and known potential adverse events. For this reason, the importance of accurate clinical records is underscored.
- c. Information to Patients. Good clinical practice includes the provision of appropriate information to patients. Each CPG discussing an unusual off-label use will address the issue of information to patients. When practicable, consideration will be given to including in an appendix an appropriate information sheet for distribution to patients, whether before or after use of the product. Information to patients should address in plain language: a) that the use is not approved by the FDA; b) the reasons why a DoD health care practitioner would decide to use the product for this purpose; and c) the potential risks associated with such use.