

JOINT TRAUMA SYSTEM CLINICAL PRACTICE GUIDELINE (JTS CPG)



Eye Trauma: Initial Care (CPG ID:03)

This CPG provides a step-by-step approach for the non-ophthalmologist in the initial evaluation and treatment of eye trauma injuries sustained in the combat theater or in remote and austere environments.

Contributors

Maj William Gensheimer, USAF, MC
 COL (Ret) Robert Mazzoli, MD
 COL Mark Reynolds, USA, MC
 Maj Brett Davies, USAF, MC
 CAPT (Ret) Joseph Pasternak, MD
 Lt Col Jonathan Ellis, USAF, MC
 LTC Won Kim, USA, MC
 CDR Eva Chou, MC, USN
 Chantal Cousineau-Krieger, MD
 Maj Jonathan Corsini, USAF, MC
 Lt Col Richard Blanch, RAMC

LTC Marcus Colyer, MC, USA
 COL Darrel K. Carlton, MC, USA
 MAJ Gary Legault, USA, MC
 CDR Kyle Miller, MC, USN
 LCDR James Zimmerman, MC, USN
 Lt Col Tighe Richardson, USAF, MC
 CDR John Cason, MC, USN
 CAPT Elizabeth Hofmeister, MC, USN
 Lt Col James R. Townley, USAF, MC
 Lt Col Matthew Caldwell, USAF, MC
 Col Stacy A. Shackelford, USAF, MC

First Publication Date: 01 Aug 2007

Publication Date: 28 Aug 2019

Publication Supersedes: 24 Nov 2014

TABLE OF CONTENTS

Background/Executive Summary.....	5
Goals of Eye Trauma Care.....	5
Priorities.....	5
Eye Exam.....	5
Management.....	5
Prevent Eye Injuries.....	6
Eye History.....	6
Initial Eye Exam.....	7
Vision.....	7
Intraocular Pressure (IOP).....	7
Pupils.....	7
Extraocular Motility.....	7
Examination.....	7
Shield and Ship.....	8
Do No Harm (Do Not's).....	8
Teleophthalmology.....	9

Prevention 9

Open Globe Injury..... 10

 Mechanism..... 10

 Exam Findings..... 10

 Management..... 10

Intraocular Foreign Body (IOFB) Injury 11

 History 11

 Exam 11

 Management..... 12

Chemical Injury 13

 Exam 13

 Management..... 13

Orbital Compartment Syndrome 14

 History 14

 Exam 14

 Management..... 15

Hyphema 15

 Exam 15

 Management..... 15

Orbital Fracture 16

 Exam 16

 Management..... 16

Eyelid Laceration..... 17

 Exam 17

 Management..... 17

Thermal Burn 17

 Exam 17

 Management..... 18

Corneal Abrasion 18

 Exam 18

 Management..... 18

Infectious Keratitis/Corneal Ulcer 19

 Exam 19

 Management..... 19

Corneal And Conjunctival Foreign Bodies..... 20

 Exam 20

 Management..... 20

Intraorbital Foreign Body..... 21

 Exam 21

 Management..... 21

Laser Exposures 21

Lasik Flap Dislocation..... 21

Traumatic Optic Neuropathy 22

Angle-Closure Glaucoma 22

 Exam 22

Management..... 22

Preseptal Cellulitis 23

 Exam..... 23

 Management..... 23

Orbital Cellulitis 23

 Exam..... 23

 Management..... 24

Protective Eyewear..... 24

Visual Acuity Testing..... 25

RAPD Testing 27

How to Place Eye Shield..... 28

Continuous Irrigation Using Nasal Cannula 28

 Supplies Needed..... 28

 Steps..... 29

Lateral Canthotomy and Inferior Cantholysis..... 29

Eye Anatomy..... 31

Aeromedical Evacuation Considerations 32

Performance Improvement (PI) Monitoring..... 32

 Intent (Expected Outcomes) 32

 Performance/Adherence Measures 33

 Data Sources..... 33

 System Reporting & Frequency..... 33

Acknowledgments 33

Responsibilities 33

References..... 34

Purpose..... 38

Background..... 38

Appendix A: Additional Information Regarding Off-Label Uses in CPGs 38

TABLE OF FIGURES

Figure 1. Eye protection worked after vehicle hit by rocket-propelled grenade.9

Figure 2. Maintain high index of suspicion for eye trauma injury even.9

Figure 3. Open globe with eyelid laceration secondary to rubber pellets from nonlethal grenade explosion.11

Figure 4. Corneal laceration and eyelid laceration.11

Figure 5. Open globe with peaked pupil and iris prolapse.11

Figure 6. Open globe with eyelid laceration secondary to rollover motor vehicle crash.11

Figure 7. Multiple foreign bodies in the cornea from an IED blast.12

Figure 8. Penetration of concrete foreign body into the eye.12

Figure 9. Same case demonstrating multiple foreign bodies in the cornea.13

Figure 10. Subtle corneal penetration from foreign body.13

Figure 11. Alkali burn with corneal opacification and blanching of conjunctiva.14

Figure 12. Irrigation.14

Figure 13. Hyphema.15

Figure 14. Entrapment of left inferior rectus muscle from left orbital floor fracture.16

Figure 15. Computed tomography showing left orbital floor and medial wall fractures.16

Figure 16. Lower eyelid laceration involving nasolacrimal system.17

Figure 17. Upper eyelid laceration.17

Figure 18. Eye and facial thermal burn.18

Figure 19. Epithelial defect with no infiltrate.19

Figure 20. Epithelial defect stains with fluorescein when illuminated with cobalt blue light.19

Figure 21. Pseudomonas infectious keratitis (corneal ulcer) from contact lens wear.20

Figure 22. Corneal metallic foreign body.20

Figure 23. Intraorbital foreign body.21

Figure 24. Acute angle closure glaucoma.22

Figure 25. Preseptal cellulitis.23

Figure 26. Orbital cellulitis.24

Figure 27. Neon green APEL logo required on MCEP packaging.25

Figure 28. APEL name permanently marked on the frame.25

Figure 29. APEL name permanently marked on eye gear frame.25

Figure 30. Visual acuity testing.27

Figure 31. Eye shields.28

Figure 32. Continuous irrigation for chemical injury using nasal cannula.29

Figure 33. Technique for lateral canthotomy and inferior cantholysis.30

Figure 34. Eye anatomy.31

Figure 35. External landmarks and extraocular muscles of the eye.31

BACKGROUND / EXECUTIVE SUMMARY

- Eye injuries are common in warfare.¹⁻³ During Operation Enduring Freedom (OEF) and Operation Iraqi Freedom (OIF) 10-15% of combat-related trauma injuries involved the eye.⁴
- Significant numbers of potentially serious eye conditions can arise during non-battle activities and environments.¹
- A large percentage of serious and/or blinding eye injuries can be prevented by wearing approved combat eye protection⁴ such as combat eye protection from the Authorized Protective Eyewear List (APEL) available at <https://www.peosoldier.army.mil/equipment/eyewear/>.
- The eye is extremely intolerant of injury.
 - Eye trauma requires prompt evaluation and treatment by an eye surgeon.
 - The foundation for successful treatment and preservation of vision is most often laid in the **initial phases** by forward medical providers at all echelons of care.
- Ophthalmic resources are deployed increasingly sparingly in very select locations.
 1. Initiate teleophthalmology consultation with eye surgeon as soon as possible. (See [Teleophthalmology](#).)
 2. Evacuate all vision-threatening injuries so that they are able to receive treatment by an eye surgeon within 24 hours if possible.
 - Factors such as combat operations, aircraft availability, weather, proximity to port, transport safety and security can affect the timing of transfer and definitive treatment.
 - When evacuation to an eye surgeon is delayed, or caring for ocular injuries in the Prolonged Field Care Environment, see the [Joint Trauma System Ocular Injuries and Vision-Threatening Conditions in Prolonged Field Care Clinical Practice Guideline, 01 Dec 2017](#).

GOALS OF EYE TRAUMA CARE

PRIORITIES

Maintain high index of suspicion based upon the mechanism of injury.

Eye Exam

- When possible, assess and document, at a minimum, visual acuity.
- Examine for critical findings. (See below.)

Management

1. Recognize and immediately treat the two traumatic eye emergencies listed below:
 - a. For chemical injury, **irrigate immediately and copiously** unless there is an open globe injury. (See [Chemical Injury](#).)

- b. For orbital compartment syndrome, perform immediate lateral canthotomy and inferior cantholysis. (See [Orbital Compartment Syndrome](#).)
2. **SHIELD AND SHIP** vision-threatening eye injuries:
 - a. Protect injured eyes (known or potential injuries) with a rigid eye shield immediately (i.e. “Eyepro” or “Fox shield”).
 - b. Maintain patient comfort.
 - c. Prevent further damage.
 - d. Do **NOT** put pressure on eye with suspected open globe injury.
 - e. Initiate teleophthalmology consultation with eye surgeon as soon as possible. (See [Teleophthalmology](#).)
 - Urgent: Call Role 3 or Role 4 with an eye surgeon (ophthalmologist).
 - Non-urgent: Contact Role 3 or Role 4 with an eye surgeon (ophthalmologist). Can use [Pacific Asynchronous TeleHealth \(PATH\)/ Health Experts online Portal \(HELP\)](#) web-based system if no ophthalmologist in theatre.
 - f. Evacuate all vision-threatening injuries so that they are able to receive treatment by an eye surgeon within 24 hours when possible.

Prevent Eye Injuries

1. Encourage wearing only approved eye protection in accordance with unit guidelines and requirements. Examples: Military Combat Eye Protection (MCEP), Ballistic Protective Eyewear (BPE), “eyepro,” or “eye armor.” (See [Protective Eyewear](#).)
2. Discourage contact lens use.

EYE HISTORY

“Keep an eye out” for eye trauma.

1. Maintain high index of suspicion based upon mechanism of injury.
 - Blast injury - most common cause eye injury in OIF and OEF.^{5,6}
 - Direct facial and eye trauma.
 - Cranial or brain injury.^{5,7}
 - Metal on metal mechanisms (metallic fragments can penetrate without obvious signs on exam).
 - Compressive blunt force trauma (can cause ruptured globe).
 - Multisystem trauma. It is easy to overlook ocular trauma.
 - Unconscious patient who cannot report vision change.
 - Thermal burns, especially to the face.
2. If patient can follow commands, ask about eye symptoms such as vision loss, decreased vision, double vision, or eye pain.

3. Ask if casualty was wearing MCEP, BPE, “Eyepro,” or “eye armor” at time of injury. Review past eye history, including use of glasses or contact lens.
4. Review tetanus status.

INITIAL EYE EXAM ⁸

VISION

1. Assess and document visual acuity for each eye if possible. (See [Visual Acuity Testing](#).)⁸
2. Presenting vision may be the best predictor of final visual outcome.⁹

INTRAOCULAR PRESSURE (IOP)

1. Do NOT put pressure on eye with suspected open globe injury.
2. If orbital compartment syndrome is suspected, palpate eyelids to see if one eye has increased firmness and resistance compared with the opposite eye (“rock hard” eyelids).
3. Do not attempt to check IOP at Role 1 or 2 unless experienced with this technique.

PUPILS

Test for relative afferent pupillary defect (RAPD) using swinging flashlight test. (See [RAPD Testing](#).)

EXTRAOCULAR MOTILITY

If patient can follow commands, ask to follow your finger without moving the head. Record any restrictions to movement.

EXAMINATION

Examine for critical findings. Perform focused eye exam “outside to inside.”

- External Exam – face, bony orbit, eyelids.
- Eye – conjunctiva, cornea, anterior chamber, iris, lens. (See [Eye Anatomy](#).)
- Unless experienced, do not attempt fundus/posterior segment examination at Role 1 or 2.
- Do NOT attempt ultrasound of the eye. It places pressure on the eye.

SHIELD AND SHIP**SHIELD AND SHIP vision-threatening eye injuries**¹⁰⁻¹¹

1. Protect injured eyes (known or potential) with a rigid eye shield immediately - Eyepro or Fox shield. (See [How to Place Eye Shield.](#))
 - a. Base protection choice upon findings of eye history and exam.
 - b. Treat eyelid injuries like an open globe.
2. Maintain patient comfort during transport.
 - a. Prevent Valsalva which can increase the risk of extrusion of intraocular contents.
 - b. Provide pain control and sedation as needed.
 - c. Treat nausea and vomiting aggressively (Promethazine 50 mg IV or Ondansetron 4-8 mg IV).
 - d. Avoid strenuous movements.
 - e. Bed rest with head elevated 30 degrees if possible.
3. Prevent further damage. **Do no harm.** (See Do No Harm Section below.)
Do NOT put pressure on eye with suspected open globe injury.
4. Initiate teleophthalmology consultation with eye surgeon as soon as possible. (See [Teleophthalmology.](#)) Provide focal history, exam, and photographs when able.
5. Evacuate all vision-threatening injuries so that they are able to receive treatment by an eye surgeon within 24 hours if possible.
 - a. There is no altitude flight restrictions for open globe (no air in closed space with this injury).
 - b. When in doubt: SHIELD AND SHIP.

DO NO HARM (DO NOT'S)

1. DO NOT let a suspected eye injury leave your level of care without rigid eye protection.
2. DO NOT patch. It puts pressure on eye. (**DO shield but DO NOT patch.**)
3. Do NOT wrap. It puts pressure on eye.
4. Do NOT place anything under an eye shield, including gauze.
5. DO NOT put pressure on eye with suspected open globe injury; it may increase the risk of extrusion of intraocular contents.
6. DO NOT check intraocular pressure at a Role 1 or 2. (Eye surgeon will check at Role 3 or 4.)
7. Do NOT attempt ultrasound of the eye. It places pressure on the eye.
8. DO NOT remove impaled or resistant foreign bodies.
9. DO NOT attempt to repair eye.
10. DO NOT enucleate or debride tissue, even if eye is severely traumatized.

TELEOPHTHALMOLOGY ¹²

1. Management of eye injuries is complex. Recommendation is to engage an eye surgeon via teleophthalmology consultation as soon as possible.
2. Teleophthalmology improves and extends ophthalmic care to remote deployed locations.
 - **Urgent:** Use phone or video teleconference service to call a Role 3 or Role 4 with an eye surgeon (ophthalmologist).
 - **Non-urgent:** Non-urgent: Contact Role 3 or Role 4 with an eye surgeon (ophthalmologist). Can use [Pacific Asynchronous TeleHealth \(PATH\)/Health Experts online Portal \(HELP\)](#) web-based system if no ophthalmologist in theatre.
3. Information to provide in consult:
 - a. Focal history: Mechanism of injury, history of eyepro use, use of glasses or contact lenses
 - b. Focal exam: Visual acuity, key exam findings
 - c. Picture(s)

PREVENTION

1. Encourage wearing only approved eye protection with MCEP, BPE, “eyepro,” or “eye armor” (protective eyewear per Unit guidelines).
2. Discourage contact lens use.

Figures 1 & 2. Eye armor will help prevent many, but not all, eye injuries. If any kind of injury involves any portion of the face that would otherwise be covered by protective spectacles or goggles, maintain high level of suspicion – regardless of obvious severity.

Figure 1. Eye protection worked after vehicle hit by rocket-propelled grenade.

Photo credit: COL Darrel K. Carlton

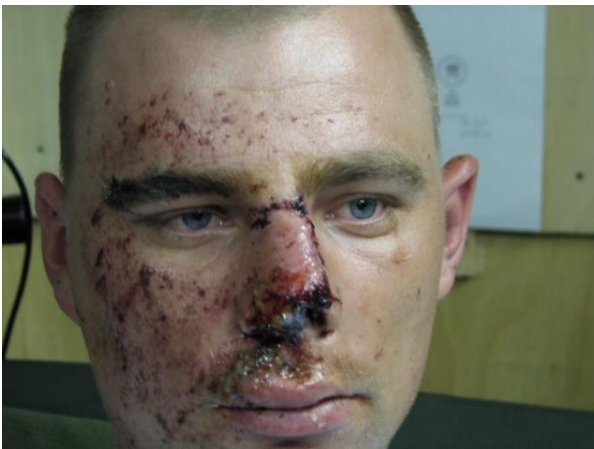
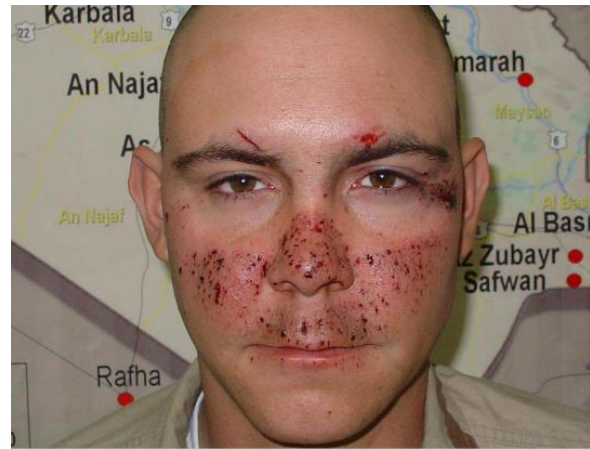
Figure 2. Maintain high index of suspicion for eye trauma injury even if not obvious.

Photo credit: COL (Ret) Thomas H. Mader, MD.



OPEN GLOBE INJURY

MECHANISM

- Laceration(s) from penetrating or perforating trauma. ¹³
- Ruptured globe from blunt trauma.

EXAM FINDINGS

- Collapsed or severely distorted eye.
- Open wound, full-thickness corneal or scleral laceration.
- Shallow anterior chamber.
- Peaked or irregular pupil.
- Prolapse of intraocular contents outside the eye. Dark tissue is iris or uveal tissue.
- Subconjunctival hemorrhage (SCH), especially if 360 degrees.

MANAGEMENT ¹⁴⁻¹⁹

1. Assess and document vision when possible.
2. Early teleophthalmology consultation with eye surgeon (See [Teleophthalmology](#)).
3. SHIELD AND SHIP
 - a. Rigid eye shield immediately.
 - b. Evacuation for urgent surgical repair within 24 hours when possible. ^{18,20-25}
4. Nothing to eat or drink.
5. Bed rest with head elevated 30 degrees if possible.
6. Avoid maneuvers that increase intraocular pressure.
7. Start systemic antibiotics. ^{14,26-34}
 - a. Moxifloxacin 400 mg PO or IV q24hrs (Alternative Levofloxacin 750 mg PO or IV q24hrs).
 - b. If available, also give Vancomycin 1 g IV q12hrs (Alternative Cefazolin 1 g IV q8hrs).
8. Treat nausea and vomiting aggressively (Ondansetron 4-8 mg IV or Promethazine 50 mg IV). Administer tetanus booster at first opportunity if needed.
9. Provide sedation and analgesia as needed (maintain patient comfort).
10. DO NOT put pressure on eye. It may increase the risk of extrusion of intraocular contents.
11. Do NOT attempt ultrasound of the eye. It places pressure on the eye.
12. Do NOT attempt to repair.
13. Do NOT attempt to enucleate eye.
14. Do NOT attempt to debride tissue, even if the eye is severely traumatized.

Figures: Open globe.

Figure 3. Open globe with eyelid laceration secondary to rubber pellets from nonlethal grenade explosion.

Photo credit: LTC Won Kim.

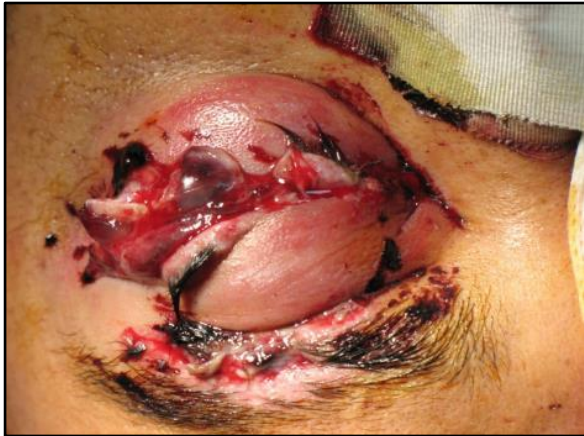

Figure 4. Corneal laceration and eyelid laceration.

Photo credit: COL Mark Reynolds.

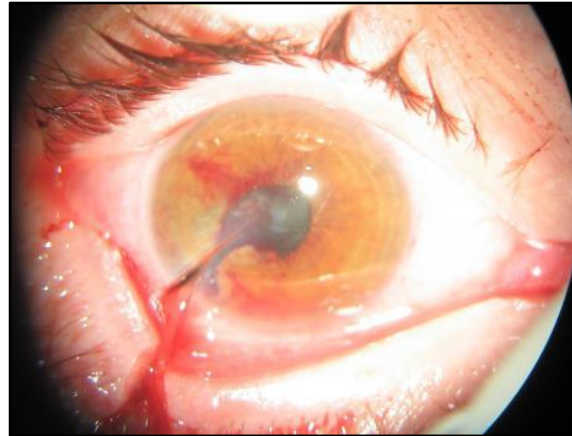


Figure 5. Open globe with peaked pupil and iris prolapse.

Photo credit: Maj Brett Davies.

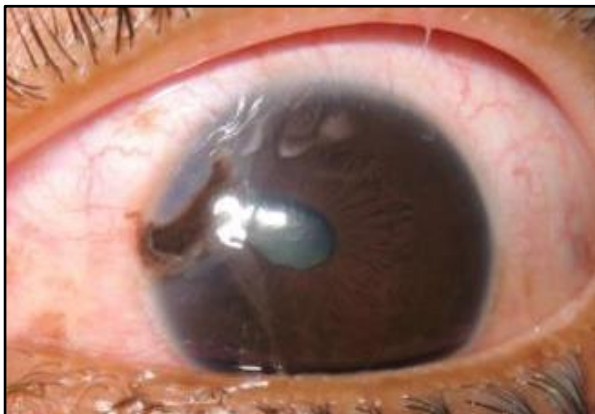
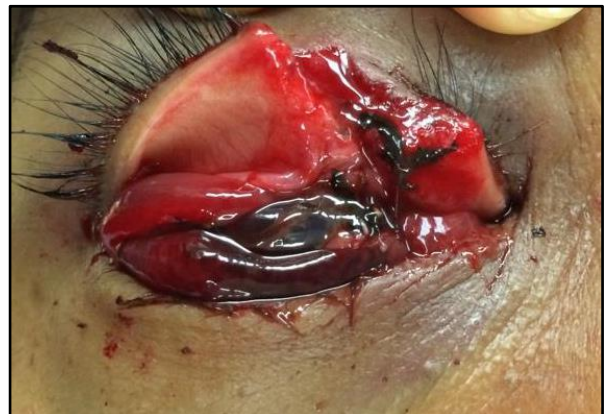

Figure 6. Open globe with eyelid laceration secondary to rollover motor vehicle crash.

Photo credit: CDR Eva Chou.



INTRAOCULAR FOREIGN BODY (IOFB) INJURY

HISTORY

High index of suspicion if blast injury, shrapnel, or metal-on-metal injury.

EXAM

- Penetrating or perforating site(s) sclera or cornea.
- Hole in iris.
- Findings may be subtle; maintain high index of suspicion.

MANAGEMENT ^{37,38}

1. Assess and document vision if possible.
2. Seek teleophthalmology consultation with eye surgeon. (See [Teleophthalmology](#).)
3. SHIELD AND SHIP
 - a. Apply rigid eye shield immediately.
 - b. Evacuate for urgent surgical repair within 24 hours if possible. ³⁸⁻⁴⁴
4. Nothing to eat or drink.
5. Bed rest with head elevated 30 degrees if possible.
6. Avoid maneuvers that increase intraocular pressure.
7. Start systemic antibiotics. ^{38,40}
 - a. Moxifloxacin 400 mg PO or IV q24hrs (Alternative Levofloxacin 750 mg PO or IV q24hrs).
 - b. If available, also give Vancomycin 1 g IV q12hrs (Alternative Cefazolin 1 g IV q8hrs).
8. Treat nausea and vomiting aggressively (Ondansetron 4-8 mg IV or Promethazine 50 mg IV).
9. Administer tetanus booster at first opportunity if needed.
10. Provide sedation and analgesia as needed.
11. Do NOT attempt to remove IOFB.
12. DO NOT put pressure on eye, it may increase the risk of extrusion of intraocular content.

Figures: Intraocular foreign body. Findings may be subtle.

Figure 7. Multiple foreign bodies in the cornea from an IED blast. Some of the foreign bodies penetrated into the eye. Most foreign material was determined to be stone.

Photo credit: CAPT (Ret) Joseph Pasternak, MD.

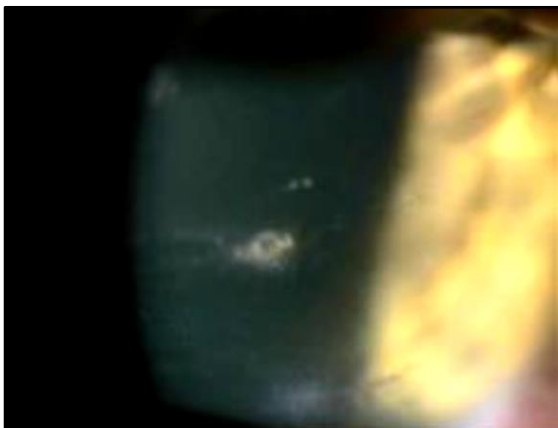


Figure 8. Penetration of concrete foreign body into the eye.

Photo credit: Lt Col Matthew Caldwell.

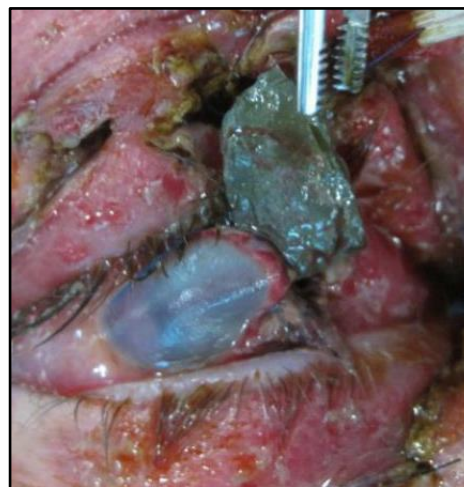

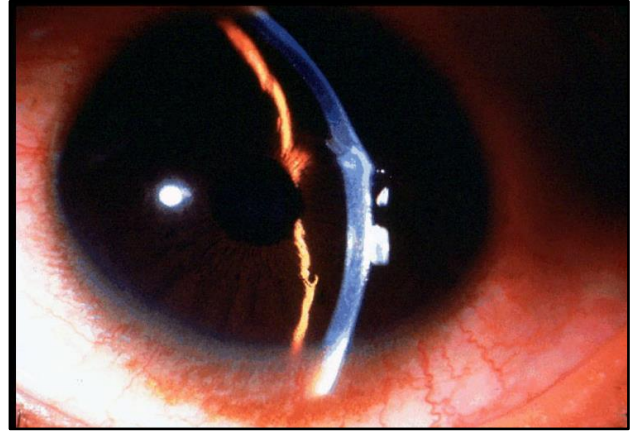
Figure 9. Same case demonstrating multiple foreign bodies in the cornea. Some foreign bodies penetrated the eye. Maintain a high index of suspicion based upon mechanism of injury.

Photo credit: CAPT (Ret) Joseph Pasternak, MD.

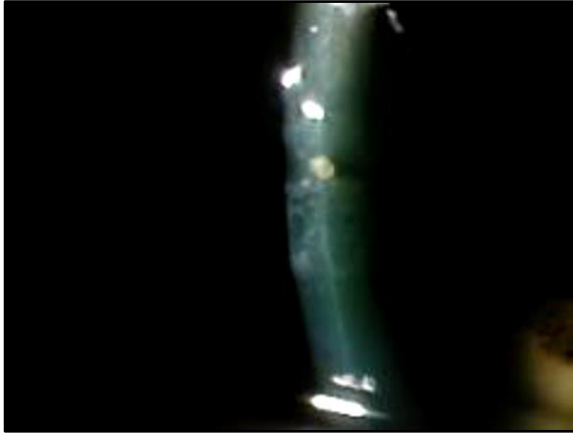

Figure 10. Subtle corneal penetration from foreign body.

Photo credit: CAPT (Ret) Joseph Pasternak, MD.



CHEMICAL INJURY

EXAM

1. Epithelial defect(s) of cornea or conjunctiva
2. Redness and swelling of conjunctiva
3. Blanching of conjunctiva
4. Corneal opacification

MANAGEMENT

1. Begin irrigation immediately unless there is an open globe injury.
 - Irrigate with normal saline or lactated ringers if available.
 - OK to use water, or any neutral irrigation solution is acceptable.
 - Can use nasal cannula hooked to IV tubing for continuous irrigation. (See [Continuous Irrigation Using Nasal Cannula.](#))
2. Use a **minimum of 2 liters** irrigation if unable to check PH. Some chemical injuries require up to 10 liters.
3. Apply topical anesthesia with tetracaine, proparacaine, or lidocaine as needed to maintain patient comfort during irrigation.
4. Do NOT try to neutralize acid with base or base with acid.
5. Remove visible acidic or basic foreign bodies with a cotton tip applicator (CTA).

6. Remember to inspect the conjunctival fornices for retained foreign bodies. Irrigate or sweep fornices with a CTA.
7. Assess and document vision if possible.
8. Seek teleophthalmology consultation with eye surgeon. (See [Teleophthalmology](#).)
9. SHIELD AND SHIP.

Figures: Chemical injury.

Figure 11. Alkali burn with corneal opacification and blanching of conjunctiva.
 Photo credit: Wills Eye Manual 7th Edition.

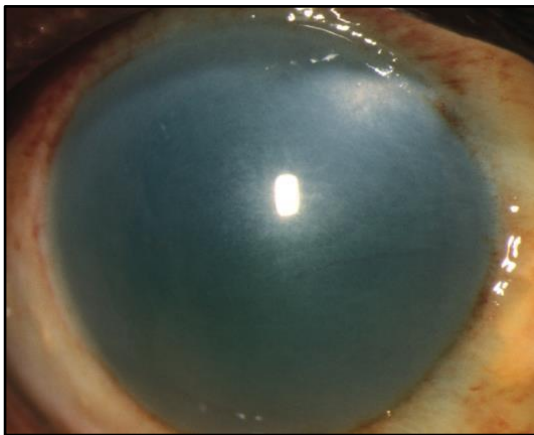
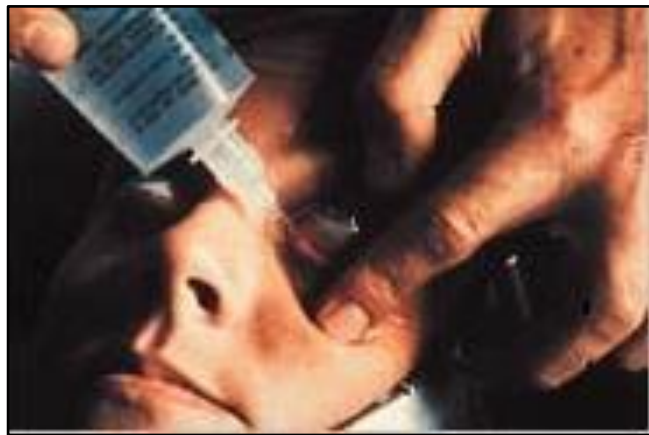

Figure 12. Irrigation. Using bottle of normal saline to irrigate the eye, patient is instructed to look in various directions while the opposite portions of the conjunctival cul-de-sac are flushed vigorously.

Photo credit: 2018 American Academy of Ophthalmology.



ORBITAL COMPARTMENT SYNDROME

HISTORY

Most common cause is **retrobulbar hemorrhage/orbital hemorrhage**.

EXAM

1. Decrease or loss of visual acuity.
2. “Rock hard” eyelids, or eyelids tight against the globe on palpation.
 Palpate eyelids to see if one eye has increased firmness and resistance compared with the opposite eye.
3. Proptosis: bulging of affected eye compared to the other.
4. Relative afferent pupillary defect (RAPD).

MANAGEMENT

1. Emergent lateral canthotomy and inferior cantholysis. (See [Lateral Canthotomy](#).)
2. Assess and document vision if possible.
3. Seek teleophthalmology consultation with eye surgeon. (See [Teleophthalmology](#).)
4. SHIELD AND SHIP.

HYPHEMA ⁴⁵

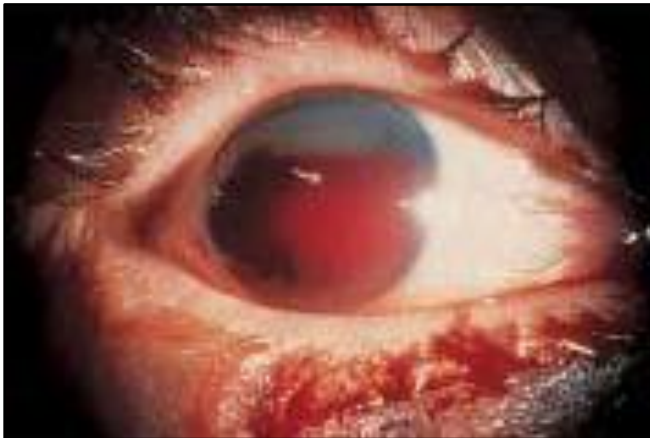EXAM

- Blood or clot in anterior chamber.
- “8-ball” or “black ball” hyphema is blood filling the anterior chamber.

MANAGEMENT

1. Rule out open globe.⁴⁶
2. Assess and document vision if possible.
3. Seek teleophthalmology consultation with eye surgeon. (See [Teleophthalmology](#).)
4. SHIELD AND SHIP.
5. Bed rest with head elevated 30 degrees if possible.

Figure 13. Hyphema. Blood filling anterior chamber.
Photo credit: 2018 American Academy of Ophthalmology.



ORBITAL FRACTURE

EXAM

- Step-off orbital rim.
- Restricted eye movements.
- Enophthalmos (affected eye is further back in orbit compared with other eye).
- Hypoglobus (affected eye is lower compared with other eye).
- Subcutaneous or conjunctival emphysema.
- Numbness below eye.

MANAGEMENT

1. Clinical evidence of extraocular muscle entrapment with nonresolving bradycardia, heart block, nausea, vomiting, or syncope requires immediate repair.
2. Assess and document vision if possible.
3. Seek teleophthalmology consultation with eye surgeon. (See [Teleophthalmology](#)).
4. SHIELD AND SHIP.
5. Consider systemic antibiotics if sinusitis or dirty wound.
6. Avoid Valsalva and maintain sinus precautions (no nose blowing).
7. Maintain high suspicion for open globe.

Figures: Orbital fracture.

Figure 14. Entrapment of left inferior rectus muscle from left orbital floor fracture. Patient is unable to look upward with left eye.

Photo credit: Maj Brett Davies.

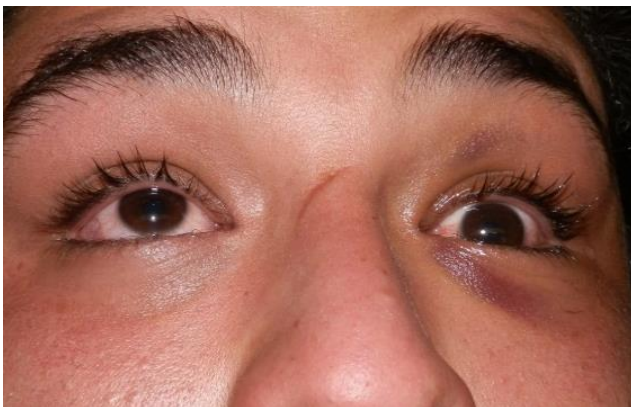
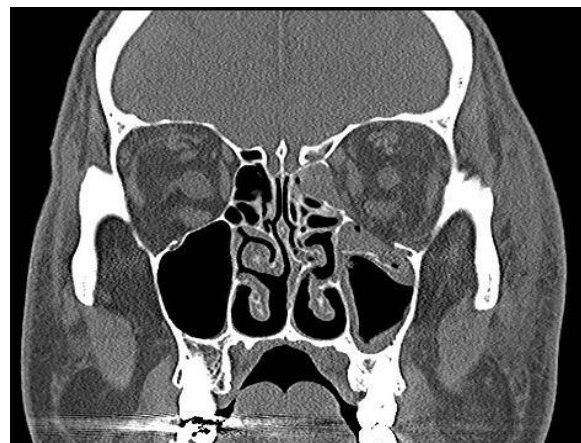
Figure 15. Computed tomography showing left orbital floor and medial wall fractures.

Photo credit: Maj Brett Davies.



EYELID LACERATION

EXAM

Note if laceration involves eyelid margin or nasolacrimal system.

MANAGEMENT

1. Maintain high suspicion for open globe.
2. Assess and document vision if possible.
3. Seek teleophthalmology consultation with eye surgeon. (See [Teleophthalmology](#).)
4. SHIELD AND SHIP.
5. Unless experienced, delay definitive repair for laceration involving eyelid margin for surgery by ophthalmologist.
6. Do NOT debride or discard tissue, even if the eye is severely traumatized.

Figures: Eyelid laceration.

Figure 16. Lower eyelid laceration involving nasolacrimal system.

Photo credit: Maj Brett Davies.

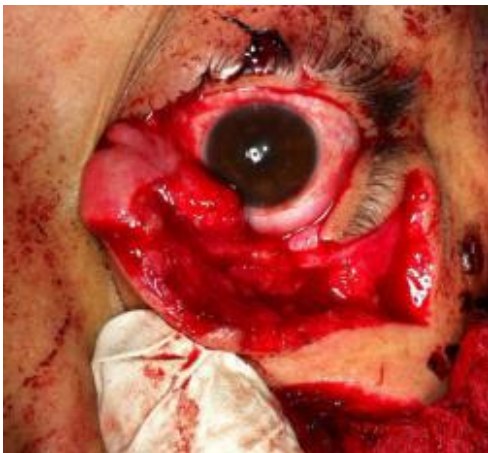
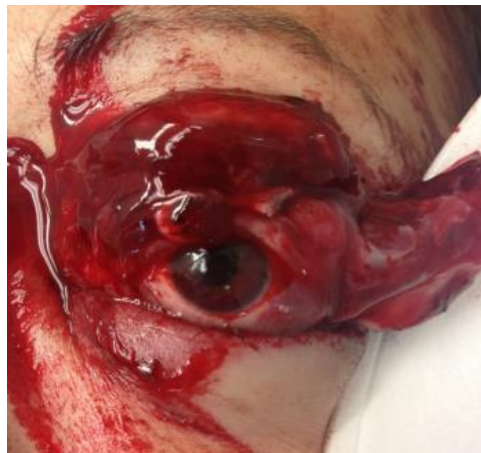
Figure 17. Upper eyelid laceration.

Photo credit: Maj Brett Davies.



THERMAL BURN

EXAM

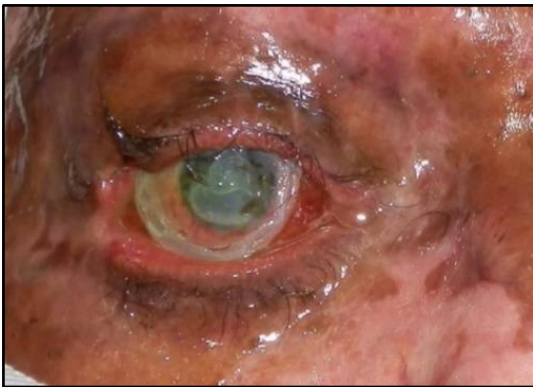- Facial burn
- Eyelid burn and eyelash loss

MANAGEMENT

1. Assess and document vision if possible.
2. Seek teleophthalmology consultation with eye surgeon. (See [Teleophthalmology](#).)
3. SHIELD AND SHIP.
4. If unable to close eyelids, start sterile eye ointment to prevent eye exposure.
 - a. Give petrolatum or erythromycin ointment if available.
 - b. Apply every 2-4 hours to eye surface.
5. Aggressive fluid resuscitation may rarely lead to orbital compartment syndrome requiring lateral canthotomy and inferior cantholysis.

Figure 18. Eye and facial thermal burn. Eye ointment on ocular surface.

Photo credit: Maj Brett Davies.



CORNEAL ABRASION

EXAM

- Epithelial defect.
- NO infiltrate (whitish opacity in cornea). Infiltrates indicate infection or inflammation of cornea.
- Stains with fluorescein when illuminated with cobalt blue light if available.

MANAGEMENT

1. Ophthalmic antibiotic ointment or drops.
 - a. Erythromycin, bacitracin, or bacitracin/polymyxin one ribbon every 2-4 hours if available.
 - b. Fluoroquinolone (e.g., moxifloxacin, gatifloxacin, levofloxacin) OR polymyxin B/trimethoprim instill one drop 4 times daily if available.
2. Stop contact lens wear.
3. Seek teleophthalmology consultation with eye surgeon. (See [Teleophthalmology](#).)

Figures: Corneal abrasion.

Figure 19. Epithelial defect with NO infiltrate.
Photo credit: CAPT (Ret) Joseph Pasternak, MD.

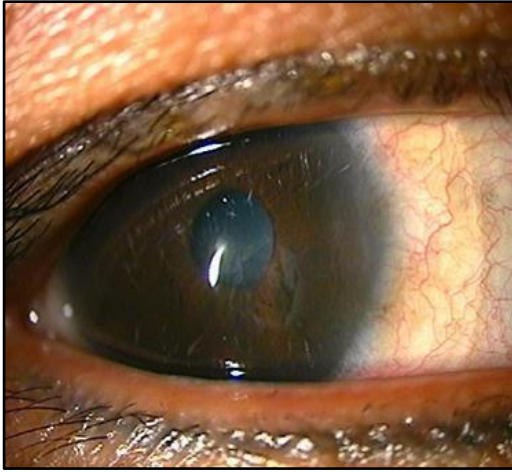
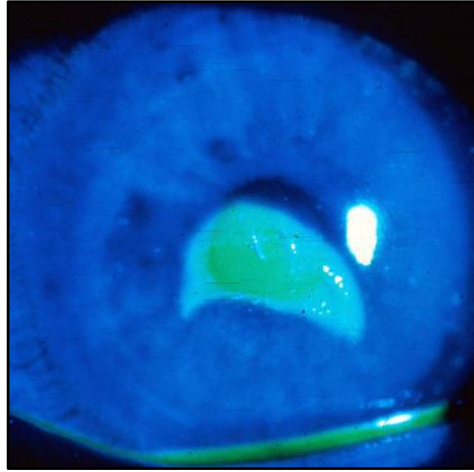


Figure 20. Epithelial defect stains with fluorescein when illuminated with cobalt blue light.
Photo credit: CAPT (Ret) Joseph Pasternak, MD.



INFECTIOUS KERATITIS / CORNEAL ULCER

These conditions are commonly associated with contact lens wear or overuse. Numerous regulations prohibit or limit wear during deployment, but contact lens use during deployment continues to be common.

EXAM

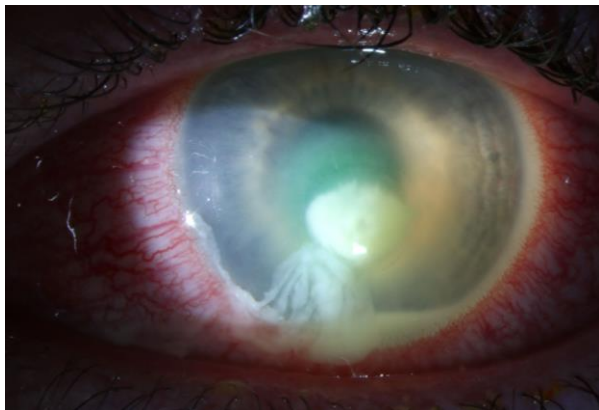
- Epithelial defect
- Corneal infiltrate (whitish opacity in cornea)

MANAGEMENT

1. Assess and document vision if possible.
2. Seek teleophthalmology consultation with eye surgeon. (See [Teleophthalmology](#)).
3. SHIELD AND SHIP.
4. Stop contact lens wear.
5. Start topical antibiotic drops if available. Instill one drop every hour while awake.
Give fluoroquinolone (e.g., moxifloxacin, gatifloxacin, levofloxacin) OR polymyxin B/trimethoprim if available.

Figure 21. Pseudomonas infectious keratitis (corneal ulcer) from contact lens wear.

Photo credit: Lt Col Chantal Cousineau-Krieger.



CORNEAL AND CONJUNCTIVAL FOREIGN BODIES

EXAM

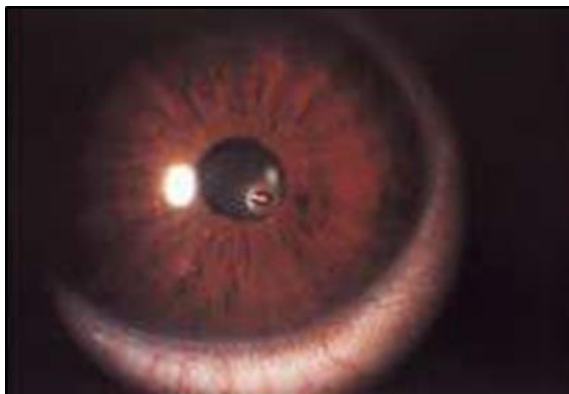- Corneal or conjunctival foreign body
- If metallic, there may be a rust ring

MANAGEMENT

1. Superficial foreign bodies may be irrigated away or removed with a moistened CTA under topical anesthesia (proparacaine or tetracaine drops).
2. Start topical ophthalmic antibiotic drops or ointments if available.
3. Do NOT remove impaled or resistant foreign bodies.
4. Assess and document vision if possible.
5. Teleophthalmology consultation with eye surgeon.
6. SHIELD AND SHIP.

Figure Number 22. Corneal metallic foreign body.

Photo credit: © 2018 American Academy of Ophthalmology.



INTRAORBITAL FOREIGN BODY

EXAM

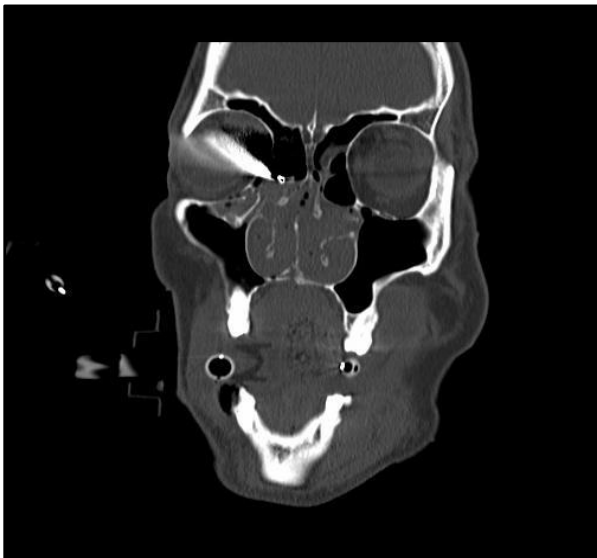Intraorbital foreign body visible on examination or identified on diagnostic imaging such as X-ray or CT.

MANAGEMENT

1. Do NOT remove impaled or resistant foreign bodies.
2. Assess and document vision if possible.
3. Seek teleophthalmology consultation with eye surgeon. (See [Teleophthalmology](#).)
4. SHIELD AND SHIP.

Figure 23. Intraorbital foreign body. Bullet in right orbit.

Photo credit: LTC Won Kim.



LASER EXPOSURES ^{47,48}

1. Assess and document vision.
2. Report incident to supervisor.
3. Consultation with flight medicine or eye care specialist.
4. Start indomethacin 25 mg PO 3 times daily. (May improve photoreceptor survival after laser injury.)⁴⁹

LASIK FLAP DISLOCATION

1. Do NOT amputate.
2. Assess and document vision if possible.

3. Seek teleophthalmology consultation with eye surgeon. (See [Teleophthalmology](#).)
4. SHIELD AND SHIP.

TRAUMATIC OPTIC NEUROPATHY

1. Assess and document vision and afferent pupillary defect.
2. Seek teleophthalmology consultation with eye surgeon. (See [Teleophthalmology](#).)
3. SHIELD AND SHIP.

ANGLE-CLOSURE GLAUCOMA

EXAM

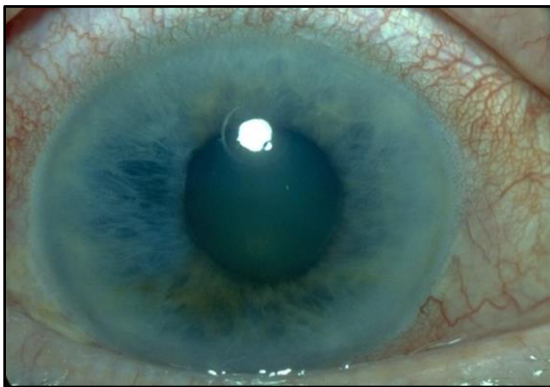
- Palpate eyelids to see if involved eye has increased firmness compared with the opposite eye.
- Fixed, mid-dilated pupil.
- Shallow anterior chamber.
- Corneal edema (hazy cornea).
- Conjunctival injection.

MANAGEMENT

1. Assess and document vision if possible.
2. Teleophthalmology consultation with eye surgeon. (See [Teleophthalmology](#).)
3. Give acetazolamide 500 mg PO initial dose, then 250 mg PO every 4 hours to decrease IOP if available.
4. Start intra ocular pressure (IOP)-lowering topical medications if available.
Instill 1 drop of timolol, brimonidine, and dorzolamide 5 minutes apart. Repeat for 3 rounds.
5. SHIELD AND SHIP.

Figure 24. Acute angle closure glaucoma.

Photo credit: LTC Won Kim.



PRESEPTAL CELLULITIS

EXAM

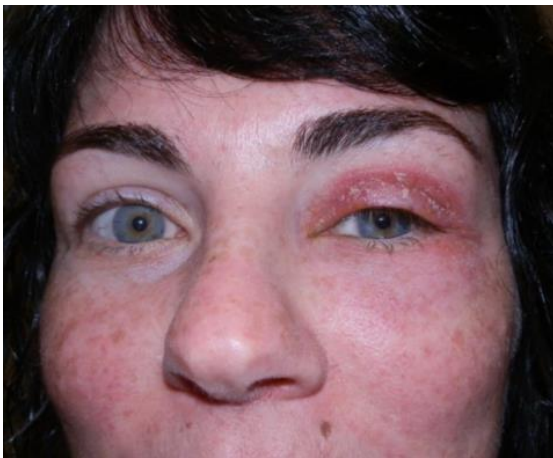- Eyelid redness, swelling, tenderness, and warmth.
- Usually little or no swelling or redness of conjunctiva.
- NO signs orbital involvement including restriction of eye movement, pain with eye movement, or proptosis (eye bulging forward), loss of vision, or afferent pupillary defect.

MANAGEMENT

1. Assess and document vision if possible.
2. Seek teleophthalmology consultation with eye surgeon. (See [Teleophthalmology](#).)
3. SHIELD AND SHIP.
4. Start oral antibiotics
Clindamycin 300 mg PO q8hrs OR Amoxicillin-clavulanic acid 875 mg PO q12hrs if available.

Figure 25. Preseptal Cellulitis.

Photo credit: Maj Brett Davies.



ORBITAL CELLULITIS

EXAM

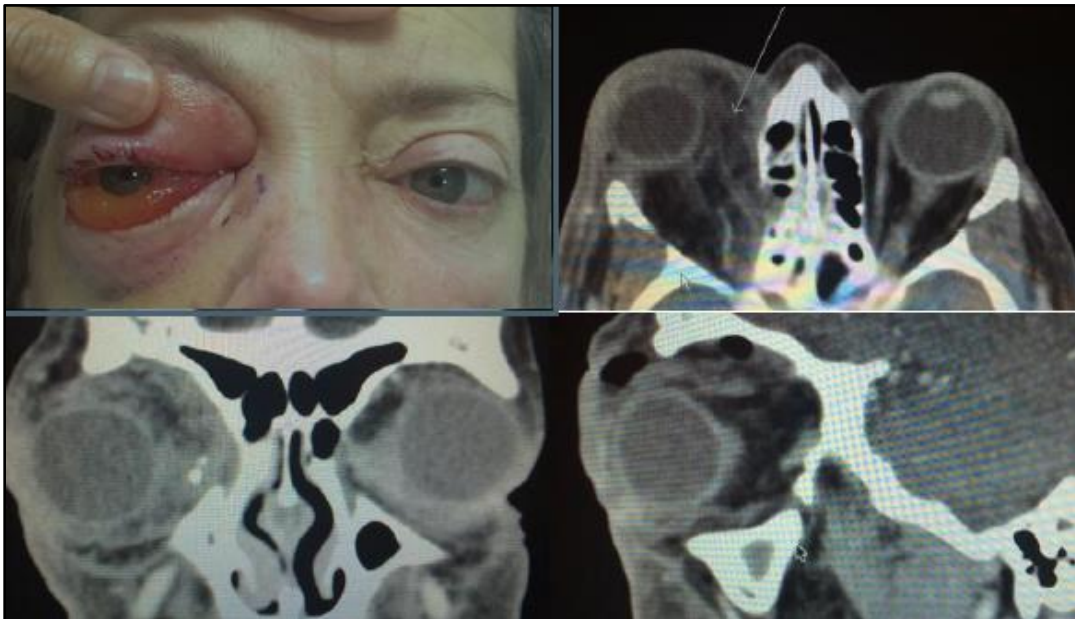
- Eyelid redness, swelling, tenderness, and warmth.
- Swelling and redness of conjunctiva.
- Signs orbital involvement may include restriction of eye movement, pain with eye movement, or proptosis (eye bulging forward), loss of vision, or afferent pupillary defect.

MANAGEMENT

1. Assess and document vision if possible.
2. Obtain urgent CT head and orbits as soon as possible to determine if there is an abscess that needs to be surgically drained.
3. Seek teleophthalmology consultation with eye surgeon. (See [Teleophthalmology](#).)
4. SHIELD AND SHIP.
5. Start broad-spectrum IV antibiotics if available.⁵⁰
 - Ampicillin-sulbactam 3 g IV q6 hours OR piperacillin-tazobactam 4.5 g IV q6 hours PLUS
 - Vancomycin 15-20 mg/kg IV per dose q8-12 hours, maximum 2 g for each dose.

Figure 26. Orbital Cellulitis. Sight-threatening infection of the right orbit.

Photo credit: CDR Eva Chou.



PROTECTIVE EYEWEAR

1. Prevent eye injuries.
 - a. Encourage wearing only approved eye protection – eyepro or eye-armor.⁵¹⁻⁵³
 - MCEP
 - BPE
 - b. Discourage contact lens use.
2. Look for the “APEL” label.
 - a. Army’s Program Executive Office – Soldier (PEO-Soldier) certifies all MCEP items to meet or exceed safety and ballistic fragmentation standards.

- b. Approved eyewear found on the APEL, available at <http://www.peosoldier.army.mil/equipment/eyewear/>
- c. APEL eyewear is identifiable by a neon green “APEL” logo required to be on all MCEP packaging and the “APEL” name permanently marked on the frame (located on left temple or strap).
- d. APEL eyepro comes in spectacle and goggle designs and in various sizes, with optical inserts available for some models.
- e. Service-specific policies may influence or limit the availability and variety of APEL eyepro.
- f. APEL eyewear should NOT be assumed to be sufficient for occupational tasks where specific safety eyewear is required (welding, chemical protection, splash protection, or other OSHA-specified tasks).
- g. Many commercial manufacturers produce “MIL-SPEC” polycarbonate eyewear, but only a few models pass the rigorous additional testing requirements.
 - Many candidate models fail because of frame failure rather than lens failure.
 - CAUTION: “Meets or exceeds MIL-SPEC” does not mean the model has passed APEL testing.
 - Be particularly vigilant and cautious when ordering eyewear or replacement eyepro online.
 - Counterfeit eyepro has surfaced in theater; beware of “bargain” eyepro. When purchasing eyepro, look for the official “APEL” marks and tags.

Figures 27, 28, 29: APEL labeling. U.S. Army Photo by PEO Soldier.

<p>Figure 27. Neon green APEL logo required on MCEP packaging.</p>	<p>Figure 28. APEL name permanently marked on the frame.</p>	<p>Figure 29. APEL name permanently marked on eye gear frame.</p>
		

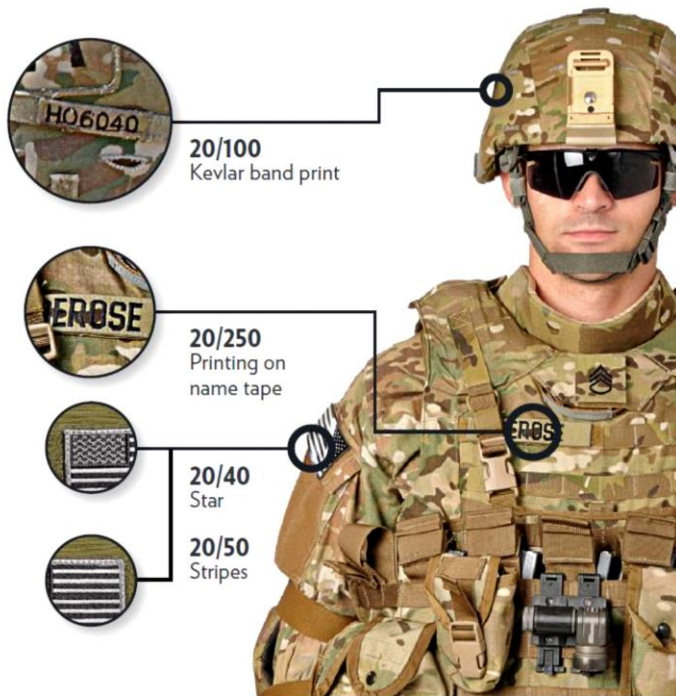
VISUAL ACUITY TESTING ⁸

1. Some patients may require drop of topical anesthetic to tolerate testing.
2. Decide upon testing method.
3. Place the patient at the designated testing distance.
 - a. Use Snellen eye chart if available. Start testing at 20 feet. Move patient closer if unable to see letters. Can move patient as close as 3 feet to chart.
 - b. Letters and patches on the uniform can be used in the field. (See Figure 30 below.) Testing distance is 3 feet.⁵⁴

- c. If patient is unable to see letters or patches, use the testing methods below:
 - Count fingers: Hold up one hand, extend one or more fingers and ask the patient to count the number of fingers. Record the greatest distance from the patient at which counting fingers is done accurately.
 - Hand motion: Hold up one hand and wave one hand. Record the greatest distance from the patient at which the patient can detect movement of your hand.
 - Light perception: Use a penlight or other bright light source and shine in the eye. Record the patient's response as light perception if able to detect the light. Record the patient's response as no light perception if unable to detect the light. Record the light source used for testing (e.g. penlight or flashlight).
4. Test with patient wearing glasses if available.
5. Record whether testing completed with or without glasses correction.
6. Test the right eye first by convention. Completely cover the left eye using the palm of your hand.
7. Do NOT put pressure on eye with suspected open globe injury.
8. If testing using letters, ask the patient to read the smallest line in which he or she can distinguish more than half the letters.
9. Record the acuity measurement as a notation (example 20/20) in which the numerator represents the distance at which the test is performed and the denominator represents the numeric designation for the line read.
10. Repeat the procedure for the other eye.
11. Record visual acuity for both eyes.
12. Example # 1
 - Right eye: uniform name tape 3 feet without correction.
 - Left eye: count fingers 2 feet without correction.
13. Example # 2
 - Right eye: hand motion 2 feet with glasses.
 - Left eye: stripes U.S. Flag patch 3 feet with glasses.

Figure 30. Visual Acuity Testing. Letters and patches on a U.S. Army uniform that can be used to determine visual acuity in the field. If using this method, test from a distance of 3 feet.

Photo credit: Vision Center of Excellence.




RAPD TESTING

1. Useful in the evaluation of unilateral or asymmetric vision loss, even in an unconscious patient.
2. “Swinging flashlight test” technique.
 - a. Use bright light source such as penlight or flashlight for testing.
 - b. If patient is able to follow commands, have patient fixate on a distant object.
 - c. Shine light into one eye and note the pupillary response.
 - d. Swing light to the opposite eye and note the pupillary response.
 - e. Move the light source deliberately from side to side while maintaining the same distance from each eye.
3. Normal response: Pupils constrict simultaneously and equally in response to light in either eye (consensual light reflex).
4. Abnormal response: When swinging light to the injured or diseased eye, the pupils constrict less or dilate (positive relative afferent pupillary defect or Marcus Gunn pupil).

HOW TO PLACE EYE SHIELD

1. Use rigid eye shield.
 - Fox shield if available. (See Figure 31a.)
 - Can use member’s own eye protection if intact or minor damage. (See Figure 31b.)
 - Other rigid materials that do not place pressure on the eye can be used as an eye shield - like a cup. (See Figure 31c.)
2. Position shield so rim of the orbit supports it when taped.
3. Secure shield with tape. Recommend 3 strips or enough to secure.
4. Shield ONLY injured eye. Shielding both eyes increases patient anxiety.
5. DO NOT patch. It puts pressure on eye. (**DO shield but DO NOT patch**).
6. Do NOT wrap. It puts pressure on eye.
7. Do NOT place anything under an eye shield including gauze.

Figure 31. Eye shields.

<i>a. Fox shield.</i>	<i>b. Can use member’s own eye protection if intact or minor damage.</i>	<i>c. Other rigid materials that do not place pressure on the eye can be used as an eye shield - like a cup.</i>
		

CONTINUOUS IRRIGATION USING NASAL CANNULA

SUPPLIES NEEDED




1. Normal saline or lactated ringers
2. IV pole
3. Pressure infuser
4. IV tubing
5. Nasal cannula
6. Connection between IV tubing and nasal cannula tubing. (See Figure 32b.)
 - Tubing connector

- Stopcock connector
- Syringe tip cap (cut off top with scissors)

STEPS

1. Apply topical anesthesia with tetracaine, proparacaine, or lidocaine.
2. Hang IV fluid on IV pole inside pressure infuser.
3. Spike and prime IV tubing.
4. Connect IV tubing to nasal cannula tubing.
5. Position nasal cannula on forehead so prongs provide continuous irrigation into both eyes.
6. Run continuous irrigation wide open.

Figure 32. Continuous irrigation for chemical injury using nasal cannula.

<p>a. Normal saline or lactated ringers inside pressure infuser.</p>	<p>b. Connectors can be used to connect IV tubing and nasal cannula tubing (left to right): tubing connector, stopcock connector, syringe tip cap (cut off top with scissors).</p>	<p>c. Position nasal cannula on forehead so prongs provide continuous irrigation into both eyes.</p>
		

LATERAL CANTHOTOMY AND INFERIOR CANTHOLYSIS

1. If possible, give subdermal injection of lidocaine 2% with epinephrine to the lateral canthus. It can be difficult to inject tissue that is already swollen.
2. Optional only if good local anesthesia. Apply a hemostat or needle driver horizontally at the lateral canthus for 1 minute to reduce bleeding.
3. Perform lateral canthotomy.
Use blunt scissors to incise the lateral canthus for 1-2 cm full thickness.
4. Perform inferior cantholysis:
 - a. With toothed forceps, grasp the lower eyelid at the edge of the incised canthus and apply traction away from the eye.

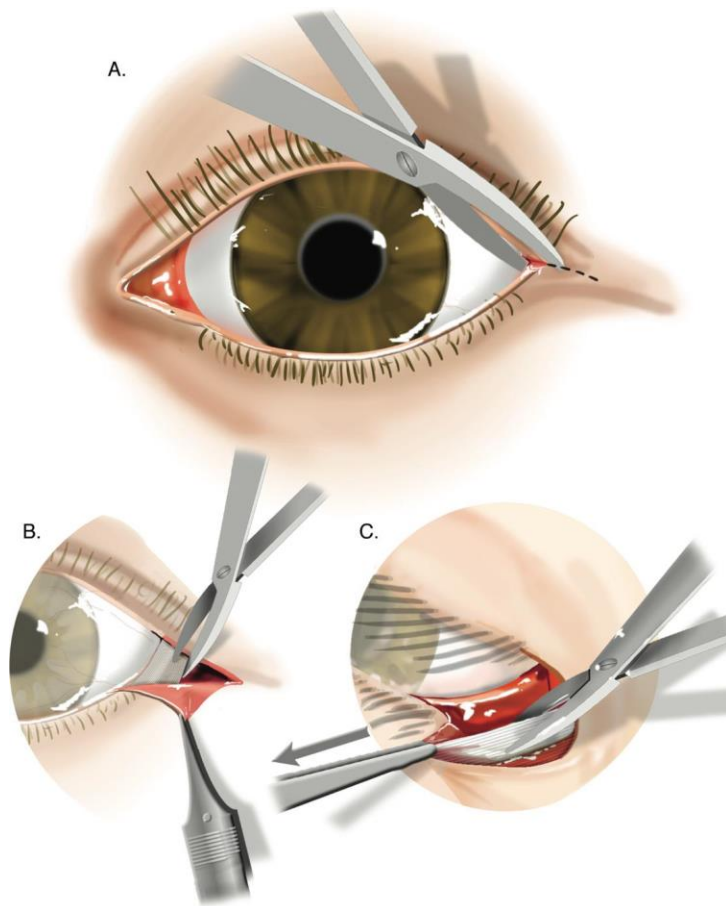
- b. Cut the inferior part (inferior crus) of the lateral canthal tendon. You may be able to palpate or “strum” the inferior part (inferior crus) of the lateral canthal tendon before cutting.
- c. If successful, the eyelid should come completely away from the globe. If the eyelid remains in its normal position, continue cutting until cantholysis is complete.

Figure 33. Technique for lateral canthotomy and inferior cantholysis.

Photo credit: Wills Eye Manual 7th Edition.

A. Perform lateral canthotomy. Use blunt scissors to incise the lateral canthus for 1-2 cm full thickness.

B and C. Perform inferior cantholysis. With toothed forceps, grasp the lower eyelid at the edge of the incised canthus and apply traction away from the eye. Cut the inferior part (inferior crus) of the lateral canthal tendon. You may be able to palpate or “strum” the inferior part (inferior crus) of the lateral canthal tendon before cutting. If successful, the eyelid should come completely away from the globe. If the eyelid remains in its normal position, continue cutting until cantholysis is complete.



EYE ANATOMY

Figure 34. Eye Anatomy.

Photo credit: 2019 American Academy of Ophthalmology.

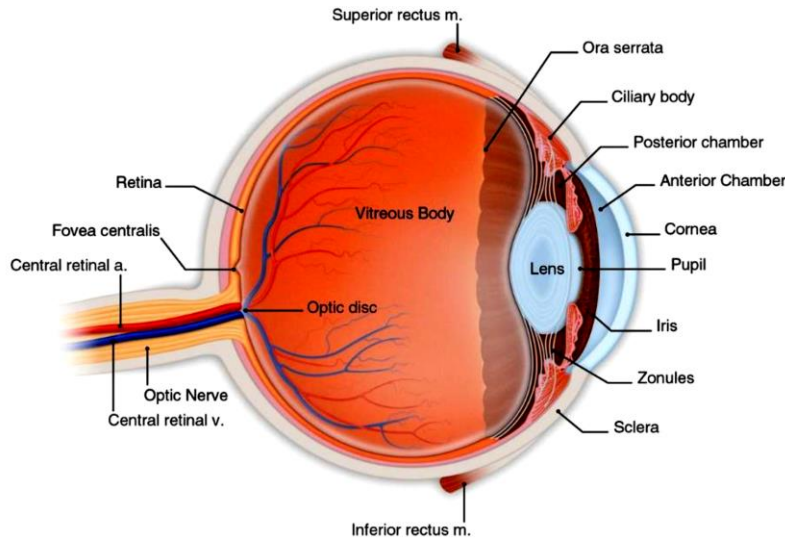
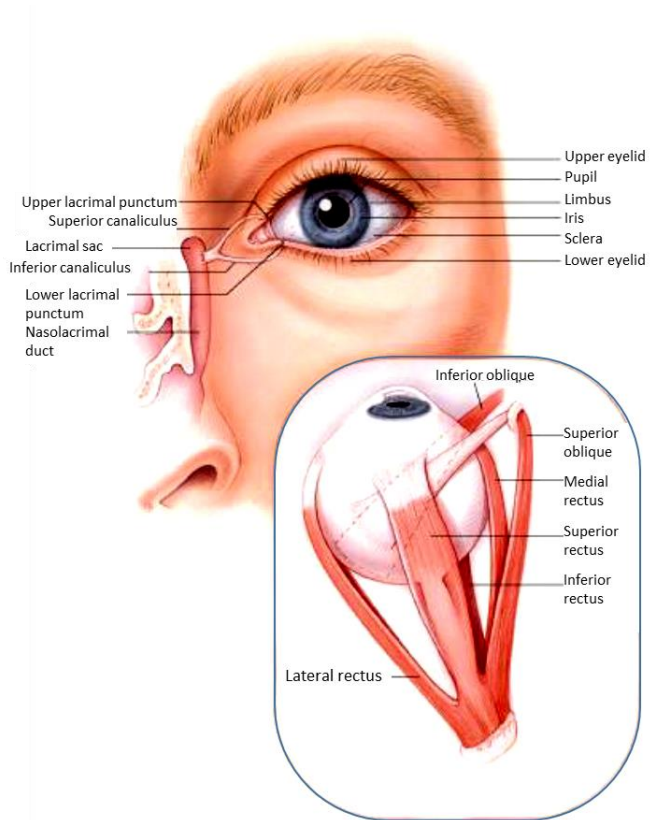


Figure 35. External landmarks and extraocular muscles of the eye.

Photo credit: 2019 American Academy of Ophthalmology.



AEROMEDICAL EVACUATION CONSIDERATIONS

Due to the requirement to move the coalition patient with vision-threatening injuries to Role 4 facilities usually out of theater, early and safe transport of these patients should involve consideration of several factors.

1. Management of concomitant injuries is crucial during flight.
2. After open globe surgery, consult with the ophthalmologist before aeromedical transport to determine if there is any trapped air in the eye.
3. Typically there is no trapped air and the patient is cleared for immediate transport. If there is any trapped air in the eye, it usually resorbs in 24-72 hours. Expansion of trapped air during flight can be catastrophic.
4. Vibration and turbulence can also be increased during flight. Adequate immobilization of foreign bodies to prevent further injury. Pain related to traumatic injuries is exacerbated by vibration and adequate pain medication is required.
5. Decreased visual input will increase the risk of motion sickness. Vomiting can increase the risk of further injury. Anti-emetics can help to mitigate this risk.
6. The need to Valsalva or perform similar maneuvers to equalize middle ear pressure can further injure the eye and surrounding structures, particularly the inferior orbit which overlies the maxillary sinuses. Adequate rapid acting decongestants (i.e. Afrin) can be used.
7. Air handling systems on board the aircraft result in a very low relative humidity. Generous use of medications to lubricate the eye may be necessary.
8. Patients with eye injuries cannot generally safely navigate inside aircraft due to poor lighting and cramped space and decrease in visual cues to balance. Consider placing the patient on a litter for safety and a non-medical attendant to help patient move if needed.

PERFORMANCE IMPROVEMENT (PI) MONITORING

INTENT (EXPECTED OUTCOMES)

- All patients with ocular injury have a documented eye and vision assessment (Tactical Combat Casualty Care (TCCC) Card (DD Form 1380)), the Resuscitation Record or elsewhere in the medical record.
- All patients with rigid eye shield placed correctly (no underlying gauze, no pressure, etc.) and documented at all roles of care (including point of injury) without an ophthalmologist.
- All patients receive appropriate antibiotic per CPG guidelines.
- All patients with an open globe injury or other indicated injuries are transferred to an ophthalmologist.

PERFORMANCE / ADHERENCE MEASURES

- All patients with ocular injury have a documented eye and vision assessment TCCC Card (DD Form 1380), the Resuscitation Record or elsewhere in the medical record.
- All patients with rigid eye shield placed correctly (no underlying gauze, no pressure, etc.) and documented at all roles of care (including point of injury) without an ophthalmologist.
- All patients receive appropriate antibiotic per CPG guidelines.
- All patients with an open globe injury are transferred to an ophthalmologist, or when indicated by injury.

DATA SOURCES

- Patient Record
- Department of Defense Trauma Registry (DoDTR)

SYSTEM REPORTING & FREQUENCY

The above constitutes the minimum criteria for PI monitoring of this CPG. System reporting will be performed annually; additional PI monitoring and system reporting may be performed as needed.

The system review and data analysis will be performed by the Joint Trauma System (JTS) Chief, JTS Program Manager, and the JTS Performance Improvement Branch.

RESPONSIBILITIES

It is the trauma team leader’s responsibility to ensure familiarity, appropriate compliance and PI monitoring at the local level with this CPG.

ACKNOWLEDGMENTS

JTS Committee of the Surgical Combat Casualty Care Voting Members	
<p>The JTS extends a special thanks to the voting members of the JTS Committee of the Surgical Combat Casualty Care for their contribution to the development and publication of this clinical practice guideline.</p>	
<ul style="list-style-type: none"> ▪ COL Scott B. Armen, MD, FACS, FCCP, FCCM, MC, USAR ▪ COL David Aaron Baker, MD, MC, FS ▪ COL Jay Baker, MD, MC, USA ▪ LTC(P) Tyson Becker, MD, MC, USA ▪ CDR Randy S. Bell MD, FAANS, MC, USN ▪ PO1 Jeffrey D. Bentley, USN USA ▪ Maj Craig (Steven) Berg, MD, USAF, MC ▪ CDR Virginia Schmied Blackman, PhD, RN, USN ▪ CAPT Matthew Bradley, MD, MC, USN ▪ Col Jeffrey (Scott) Calder, MD, USAF, MC ▪ SSG Tommy Chavez, MC, USA 	<ul style="list-style-type: none"> ▪ MAJ Keith Jackson, MD, MC, USA ▪ SFC Jonathan R. Johnson, ,OPS NCOIC, USA ▪ SMSgt Melissa A. Johnson, USAF, MC ▪ CDR Michel Kearns, MD, MC, USN ▪ Lt Col Peter A. Learn, MD, USAF, MC ▪ MAJ Rich Lesperance MD, MC, USA ▪ Maj Justin D. Manley, FS, USAF, MC ▪ CPT Alex Merkle, USA, PA ▪ CDR Margaret M. Moore, MD, FACS, MC, USNR ▪ COL Shawn Nessen, MD, MC, USA ▪ SMSgt Jose Arias-Patino, USAF

JTS Committee of the Surgical Combat Casualty Care Voting Members	
<ul style="list-style-type: none"> ▪ LTC John Chovanes, DO, FACS, MC, USAR ▪ LTC Jason B. Corley, MD, MC, USA ▪ SCPO Michael T. Denoyer, USN, USMC (USA) ▪ COL Brian Eastridge, MD, MC, USAR ▪ LTC Matthew Eckert, MD, MC, USA ▪ CAPT Ted Edson, MD, MC, USN ▪ CAPT Eric Elster, MD, FACS, MC, USN ▪ Col Mark D. Ervin, FS, USAF, MC ▪ MAJ Colin Frament, PA, MC, USA ▪ COL Tamara Funari, RN, MC, USA ▪ Brian J. Gavitt, MD, MPH, FACS, USAF, MC ▪ COL Kirby Robert Gross, MD, MC, USA ▪ Maj Andrew Hall, MD, USAF, MC ▪ LCDR Jonathan Hamrick, USN CRNA, NMCP VA ▪ COL Jason Hiles, MD, MC, USA 	<ul style="list-style-type: none"> ▪ CDR Travis Polk, MD, FACS, MC, USN ▪ CAPT Robert Ricca, MD, MC, USN ▪ Anne Rizzo MD, FACS ▪ Col James B. Sampson, MD, RPVI, FACS, USAF, MC ▪ COL Martin Schreiber, MD, MC, USAR ▪ COL Jason M. Seery, MD, FACS ▪ CAPT Zsolt Stockinger, MD, MC, USN ▪ CDR Matthew D. Tadlock, MD, FACS, MC, USN ▪ Maj Regina Tai-see, USAF, MC ▪ LTC Eric Verwiebe, MC, USA ▪ Matthew Welder, DNP, CRNA ▪ COL Christopher White, MD, MC, USA ▪ COL Paul White, MC, USA ▪ Col Eveline F. Yao, USAF, MC, CFS

REFERENCES

1. Mader TH, Aragones JV, Chandler AC, et al. Ocular and ocular adnexal injuries treated by United States military ophthalmologists during Operations Desert Shield and Desert Storm. *Ophthalmology*. 1993 Oct;100(10):1462-7.
2. Thach AB, Johnson AJ, Carroll RB, et al. Severe eye injuries in the war in Iraq, 2003–2005. *Ophthalmology*. 2008 Feb;115(2):377–82.
3. Blanch RJ, Bindra MS, Jacks AS, Scott RA. Ophthalmic injuries in British Armed Forces in Iraq and Afghanistan. *Eye (Lond)*. 2011;25(2):218-23.
4. Office of the Surgeon General, Department of the Army. Combat casualty care: Lessons learned from OEF and OIF, Chapter 7 Ocular Trauma, Borden Institute; 2012: 299-342. <https://archive.org/details/CombatCasualtyCare/page/n315> Accessed May 2019.
5. Weichel ED, Colyer MH. Combat ocular trauma and systemic injury. *Curr Opin Ophthalmol*. 2008 Nov;19(6):519-25.
6. Johnson AJ. Eye trauma management: OIF clinical considerations. *J Trauma* 2007; 62(6 Suppl):S20–S21.
7. Cho RI, Bakken HE, Reynolds ME, et al. Concomitant cranial and ocular combat injuries during Operation Iraqi Freedom. *J Trauma* 2009 Sep;67(3):516-20.
8. Allen RC, Harper RA, Eds. *Basic Ophthalmology: Essentials for Medical Students*. 10th ed. San Francisco, CA: American Academy of Ophthalmology; 2017.
9. Greven CM, Engelbrecht NE, Slusher MM, Nagy SS. Intraocular foreign bodies: management, prognostic factors, and visual outcomes. *Ophthalmology*. 2000 Mar;107(3):608-12.
10. Office of the Surgeon General, Department of the Army, Thach AB, ed. *Ophthalmic care of the combat casualty; Textbook of Military Medicine*. Borden Institute; 2003.

11. Office of the Surgeon General, Department of Army. Emergency War Surgery, Ocular Injuries. 4th U.S. Edition. Chap 14. Borden Institute; 2013: 205-218.
12. Mines MJ, Bower KS, Lappan CM, et al. The United States Army Ocular Teleconsultation program 2004 through 2009. *Am J Ophthalmol*. 2011 Jul;152(1):126-132.e2.
13. Colyer MH, Chun DW, Bower KS, Dick JS, Weichel ED. Perforating globe injuries during operation Iraqi Freedom. *Ophthalmology*. 2008 Nov;115(1):2087-93.
14. Gerstenblith AT, Rabinowitz MP, eds. *The Wills Eye Manual: Office and Emergency Room Diagnosis and Treatment of Eye Disease*. 7th ed. Philadelphia: Lippincott; 1994.
15. Lieb DF, Scott IU, Flynn HW Jr, Miller D, Feuer WJ. Open globe injuries with positive intraocular cultures: factors influencing final visual acuity outcomes. *Ophthalmology*. 2003 Aug;110(8):1560-6.
16. Ahmed Y, Schimel AM, Pathengay A, et al. Endophthalmitis following open-globe injuries. *Eye (Lond)*. 2012 Feb;26(2):212-7.
17. Miller JW ed. Benchmark protocols for managing eye trauma. Eye Insights Issue 1: Ocular Trauma. <https://eye.hms.harvard.edu/eyeinsights/2014-april/benchmark-protocols-managing-eye-trauma>. April 2014. Accessed 27 Dec 2018.
18. Andreoli CM, Andreoli MT, Kloek CE, et al. Low rate of endophthalmitis in a large series of open globe injuries. *Am J Ophthalmol*. 2009 Apr;147(4):601-608.e2.
19. US Eye Injury Registry. USEIR website <https://useir.org/> Accessed Dec 2018.
20. Bhagat N, Nagori S, Zarbin M. Post-traumatic Infectious Endophthalmitis. *Surv Ophthalmol*. 2011 May-Jun;56(3):214-51.
21. Kuhn F, Pieramici D, eds. *Ocular trauma: Principles and practice*. New York, NY: Thieme; 2002: 293-300.
22. Essex RW, Yi Q, Charles PG, Allen PJ. Post-traumatic endophthalmitis. *Ophthalmology*. 2004 Nov;111(11):2015-22.
23. Zhang Y, Zhang MN, Jiang CH, Yao Y, Zhang K. Endophthalmitis following open globe injury. *Br J Ophthalmol*. 2010 Jan;94(1):111-4.
24. Schmidseeder E, Miño de Kaspar H, Klauss V, Kampik A. Post-traumatic endophthalmitis after penetrating eye injuries. Risk factors, microbiological diagnosis and functional outcome. *Ophthalmologie*. 1998 Mar;95(3):153-7.
25. Blanch RJ, Bishop J, Javidi H, Murray PI. Effect of time to primary repair on final visual outcome after open globe injury. *Br J Ophthalmol*. 2019 Jan 12.
26. Oztürk F, Kortunay S, Kurt E, et al Penetration of topical and oral ciprofloxacin into the aqueous and vitreous humor in inflamed eyes. *Retina*. 1999;19(3):218-22.
27. Oztürk F, Kortunay S, Kurt E, et al. Effects of trauma and infection on ciprofloxacin levels in the vitreous cavity. *Retina*. 1999;19(2):127-30.
28. Hariprasad SM, Mieler WF, Holz ER. Vitreous and aqueous penetration of orally administered gatifloxacin in humans. *Arch Ophthalmol*. 2003 Mar;121(3):345-50.
29. Fuller JJ, Marcus DM. Vitreous and aqueous penetration of orally administered gatifloxacin in humans. *Arch Ophthalmol*. 2004 Sep;122(9):1408-9; author reply 1409.

30. Vedantham V, Lalitha P, Velpandian T, et al. Vitreous and aqueous penetration of orally administered moxifloxacin in humans. *Eye (Lond)*. 2006 Nov;20(11):1273-8. Epub 2006 Sep 30.
31. Al-Omran AM, Abboud EB, Abu El-Asrar AM. Microbiologic spectrum and visual outcome of posttraumatic endophthalmitis. *Retina*. 2007;27(2):236.
32. Duch-Samper AM, Chaqués-Alepuz V, Menezo JL, et al. Endophthalmitis following open-globe injuries. *Curr Opin Ophthalmol*. 1998;9(3):59.
33. Affeldt JC, Flynn HW Jr, Forster RK, et al. Microbial endophthalmitis resulting from ocular trauma. *Ophthalmology*. 1987;94(4):407.
34. Soheilian M, Rafati N, Mohebbi MR, et al. Prophylaxis of acute posttraumatic bacterial endophthalmitis: a multicenter, randomized clinical trial of intraocular antibiotic injection, report 2. *Arch Ophthalmol*. 2007 Apr;125(4):460-5.
35. Wadia S, Bhola R, Lorenz D, et al. Ketamine and intraocular pressure in children. *Ann Emerg Med*. 2014 Oct;64(4):385-388.
36. Halstead SM, Deakyne SJ, Bajaj L, et al. The effect of ketamine on intraocular pressure in pediatric patients during procedural sedation. *Acad Emerg Med*. 2012 Oct;19(10):1145-50.
37. Ehlers JP, Kunimoto DY, Ittoop S, et al. Metallic intraocular foreign bodies: characteristics, interventions, and prognostic factors for visual outcome and globe survival. *Am J Ophthalmol*. 2008 Sep;146(3):427-433.
38. Woodcock MG, Scott RA, Huntbach J, Kirkby GR. Mass and shape as factors in intraocular foreign body injuries. *Ophthalmology*. 2006 Dec;113(12):2262-9.
39. Yang CS, Lu CK, Lee FL, et al. Treatment and outcome of traumatic endophthalmitis in open globe injury with retained intraocular foreign body. *Ophthalmologica*. 2010;224(2):79-85.
40. Colyer MH, Weber ED, Weichel ED, et al. Delayed intraocular foreign body removal without endophthalmitis during OIF and OEF. *Ophthalmology* 2007 Aug; 114(8):1439–47.
41. Jonas JB, Knorr HL, Budde WM. Prognostic factors in ocular injuries caused by intraocular or retrobulbar foreign bodies. *Ophthalmology*. 2000 May;107(5):823-8.
42. Thompson JT, Parver LM, Enger CL, et al. Infectious endophthalmitis after penetrating injuries with retained intraocular foreign bodies. National Eye Trauma System. *Ophthalmology*. 1993 Oct;100(10):1468-74.
43. Jonas JB, Budde WM. Early versus late removal of retained intraocular foreign bodies. *Retina*. 1999;19(3):193-7.
44. Ferrari TM, Cardascia N, Di Gesù I, et al. Early versus late removal of retained intraocular foreign bodies. *Retina*. 2001;21(1):92-3.
45. Cockerham GC, Rice TA, Hewes EH, et al. Closed-eye ocular injuries in the Iraq and Afghanistan wars. *N Engl J Med*. 2011 Jun 2;364(22):2172-3.
46. Weichel ED, Colyer MH, Ludlow SE, et al. Combat ocular trauma visual outcomes during operations Iraqi and enduring freedom. *Ophthalmology*. 2008 Dec;115(12):2235-45.
47. Harris MD, Lincoln AE, Amoroso PJ, et al. Laser eye injuries in military occupations. *Aviat Space Environ Med*. 2003 Sep;74(9):947-52.

48. Gooch JM, Harvey RR, Parham-Bruce W, et al. U.S. Air Force School of Aerospace Medicine Laser Injury Guidebook, Apr 2012.
https://www.researchgate.net/publication/277750059_United_States_Air_Force_School_of_Aerospace_Medicine_Laser_Injury_Guidebook. Accessed Aug 2019.
49. Brown J Jr, Hacker H, Schuschereba ST, et al. Steroidal and nonsteroidal anti-inflammatory medications can improve photoreceptor survival after laser retinal photocoagulation. *Ophthalmology* 2007 Oct; 114(10):1876-83.
50. Howe L, Jones NS. Guidelines for the management of periorbital cellulitis/abscess. *Clin Otolaryngol Allied Sci.* 2004 Dec;29(6):725-8.
51. Thomas R, McManus JG, Johnson A, et al. Ocular injury reduction from ocular protection use in current combat operations. *J Trauma.* 2009 Apr;66(4 Suppl):S99-103.
52. Gondusky JS, Reiter MP. Protecting military convoys in Iraq: an examination of battle injuries sustained by a mechanized battalion during Operation Iraqi Freedom II. *Mil Med.* 2005 Jun;170(6):546-9.
53. Breeze J, Allanson-Bailey LS, Hunt NC, et al. Surface wound mapping of battlefield ocularo-facial injury. *Injury.* 2012 Nov;43(11):1856-60.
54. Godbole NJ, Seefeldt ES, Raymond WR, et al. Simplified method for rapid field assessment of visual acuity by first responders after ocular injury. *Mil Med.* 2018 Mar 1;183(suppl_1):219-223.

APPENDIX A: ADDITIONAL INFORMATION REGARDING OFF-LABEL USES IN CPGS

PURPOSE

The purpose of this Appendix is to ensure an understanding of DoD policy and practice regarding inclusion in CPGs of “off-label” uses of U.S. Food and Drug Administration (FDA)–approved products. This applies to off-label uses with patients who are armed forces members.

BACKGROUND

Unapproved (i.e. “off-label”) uses of FDA-approved products are extremely common in American medicine and are usually not subject to any special regulations. However, under Federal law, in some circumstances, unapproved uses of approved drugs are subject to FDA regulations governing “investigational new drugs.” These circumstances include such uses as part of clinical trials, and in the military context, command required, unapproved uses. Some command requested unapproved uses may also be subject to special regulations.

ADDITIONAL INFORMATION REGARDING OFF-LABEL USES IN CPGS

The inclusion in CPGs of off-label uses is not a clinical trial, nor is it a command request or requirement. Further, it does not imply that the Military Health System requires that use by DoD health care practitioners or considers it to be the “standard of care.” Rather, the inclusion in CPGs of off-label uses is to inform the clinical judgment of the responsible health care practitioner by providing information regarding potential risks and benefits of treatment alternatives. The decision is for the clinical judgment of the responsible health care practitioner within the practitioner-patient relationship.

ADDITIONAL PROCEDURES**Balanced Discussion**

Consistent with this purpose, CPG discussions of off-label uses specifically state that they are uses not approved by the FDA. Further, such discussions are balanced in the presentation of appropriate clinical study data, including any such data that suggest caution in the use of the product and specifically including any FDA-issued warnings.

Quality Assurance Monitoring

With respect to such off-label uses, DoD procedure is to maintain a regular system of quality assurance monitoring of outcomes and known potential adverse events. For this reason, the importance of accurate clinical records is underscored.

Information to Patients

Good clinical practice includes the provision of appropriate information to patients. Each CPG discussing an unusual off-label use will address the issue of information to patients. When practicable, consideration will be given to including in an appendix an appropriate information sheet for distribution to patients, whether before or after use of the product. Information to patients should address in plain language: a) that the use is not approved by the FDA; b) the reasons why a DoD health care practitioner would decide to use the product for this purpose; and c) the potential risks associated with such use.