

JOINT TRAUMA SYSTEM CLINICAL PRACTICE GUIDELINE (JTS CPG)



Urologic Trauma Management (CPG ID: 42)

Provides indications for and the procedures associated with the initial management of genitourinary (GU) trauma sustained in combat casualties.

Contributors

COL James Jezoir, MC, USA
MAJ Steve Hudak, MC, USA
LTC Jack Walters, MC, USA

CAPT Zsolt Stockinger, MC, USN
COL(ret) Steve Waxman, MC, USA

First Publication Date: 18 Nov 2004

Publication Date: 01 Nov 2017

Supersedes CPG dated 02 Apr 2012

Opinions, interpretations, conclusions, and recommendations are those of the authors and are not necessarily endorsed by the Services or DoD.

TABLE OF CONTENTS

Background.....	2
Evaluation and Treatment.....	2
Initial Evaluation	2
Renal Trauma	4
Bladder Trauma	5
Urethral Trauma	5
External Genitalia	5
Performance Improvement (PI) Monitoring	6
Intent (Expected Outcomes)	6
Performance/Adherence Measures.....	6
Data Source.....	7
System Reporting & Frequency.....	7
Responsibilities.....	7
References.....	7
Appendix A: Urological Diagnosis and Treatments	9
Appendix B: Additional Information Regarding Off-Label Uses in CPGs	12

BACKGROUND

Genitourinary (GU) trauma accounts for 10% of all combat casualties incurred during current US conflicts.¹ Management requires a systematic approach to imaging and treatment that adheres to established surgical and trauma principals. These guidelines provide direction for the identification of life threatening GU injuries, control of hemorrhage, establishment of urinary drainage, and the preservation of function where possible. Critical to initial evaluation is the hemodynamic stability of the patient. Stable patients are afforded a rigorous radiographic evaluation that identifies genitourinary sites of hemorrhage and injury and allows for the safe establishment of urinary drainage. Unstable patients benefit from rapid surgical evaluation and hemorrhage control. Preservation of as much tissue as possible, particularly when dealing with the external genitalia, should be an additional goal for far forward surgical units.² Current combat care principles allow for multiple surgical evaluations along the path of evacuation to tertiary centers outside the theater of operations where tissue re-evaluation, wound irrigation, and further debridement can occur.³

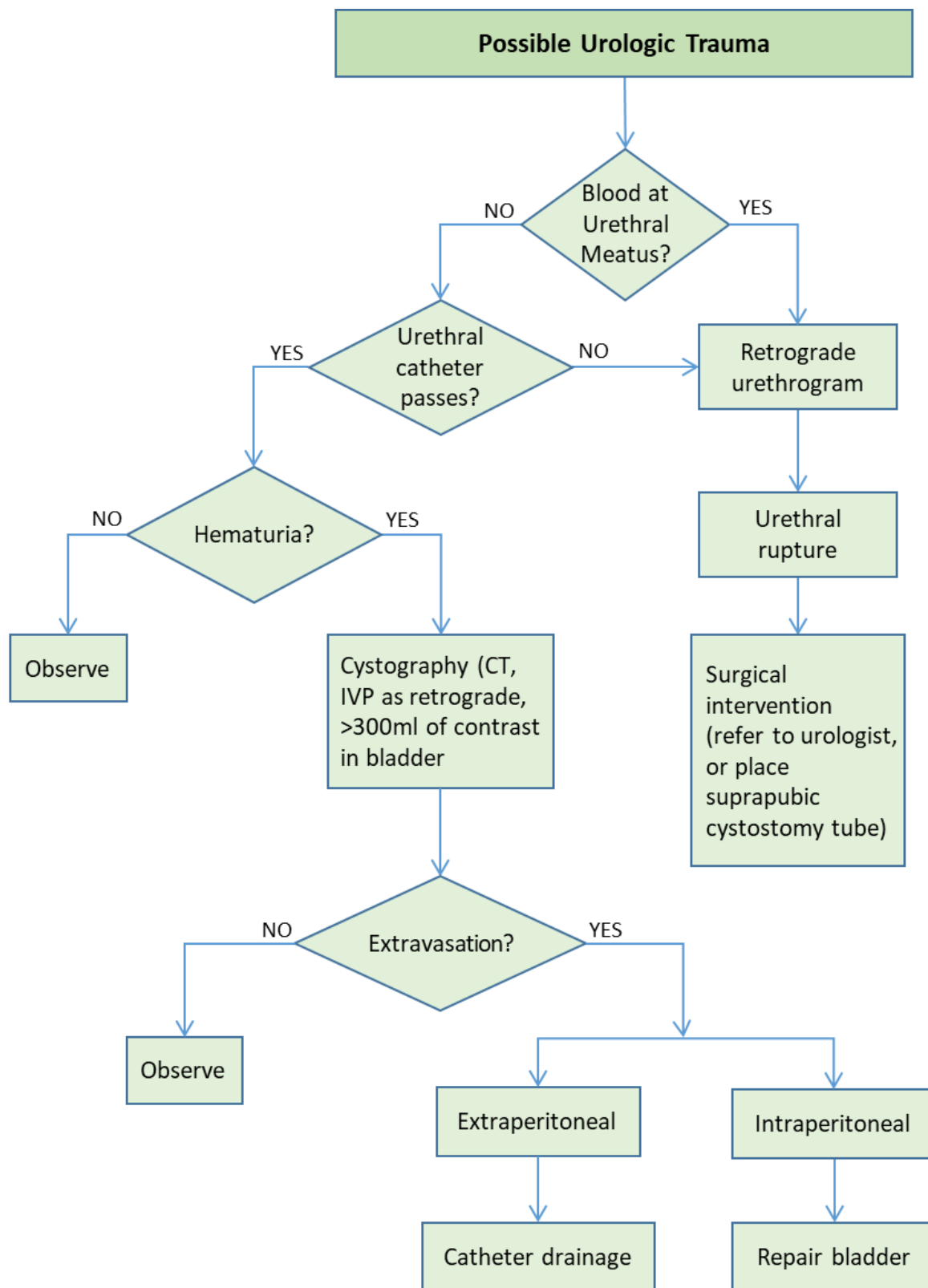
EVALUATION AND TREATMENT

Ten percent of all combat casualties in current U.S. conflicts have GU injuries, which may be blunt or penetrating in nature. The extensive use of improvised explosive devices (IED) has resulted in a substantial number of penetrating injuries that include GU organs as part of a complex wounding pattern with trauma to the abdomen, pelvis, perineum, and extremities.^{1,4-7} A significant reduction in kidney injuries has been noted in combat casualties wearing body armor.⁸ Not surprisingly, given the mechanism of injury, the most commonly injured GU structures are the external genitalia and lower urinary tract (bladder and urethra).^{4,9,10} A thorough trauma evaluation is therefore mandatory in all severely injured patients and should include proper Advanced Trauma Life Support (ATLS) based initial evaluation and management.

INITIAL EVALUATION

Severely injured patients typically warrant immediate urethral catheter placement to facilitate urinary drainage and assist with hemodynamic monitoring via hourly assessment of urine output. Prior to catheter placement, if blood is present at the urethral meatus, urethral injury is likely and retrograde urethrography is needed (See [Figure 1. Algorithm for Urologic Trauma](#) below).¹¹ A urinalysis should be obtained after successful catheter placement and the presence of gross hematuria should be immediately noted. Evaluation for renal injury is necessary in hemodynamically stable blunt trauma patients with gross hematuria or microscopic hematuria and systolic BP < 90 mmHg; or in patients with mechanism of injury or physical examination findings suggestive of renal injury (i.e. rapid deceleration, rib fracture(s), flank ecchymosis, or a penetrating injury to the abdomen, flank, or lower chest).¹¹ The stability of the patient, operational environment and capabilities of the medical treatment facility will dictate what resources for radiographic and surgical evaluation are available at each echelon of care. The preferred imaging test to evaluate for renal and ureteral injury is an intravenous (IV) contrast enhanced computed tomography (CT) with delayed imaging.¹¹ If unavailable, “one shot” Intravenous Pyelography (IVP) can be performed. During the initial evaluation of patients with hematuria, it is important to note that the severity of hematuria (gross or microscopic) does not necessarily correlate to the severity of injury.¹² For example, it is possible to have minimal hematuria despite high grade renal injury such as disruption of the ureteropelvic junction, pedicle injuries, and segmental arterial thrombosis.⁹ Conversely, low grade renal injury can result in ongoing gross hematuria. Thus, proper injury staging is critical regardless of hematuria severity. In cases of blunt renal trauma, most injuries can be managed conservatively. The grading scale is listed in [Renal Injury](#) in [Appendix A: Urological Diagnosis and Treatments.](#))

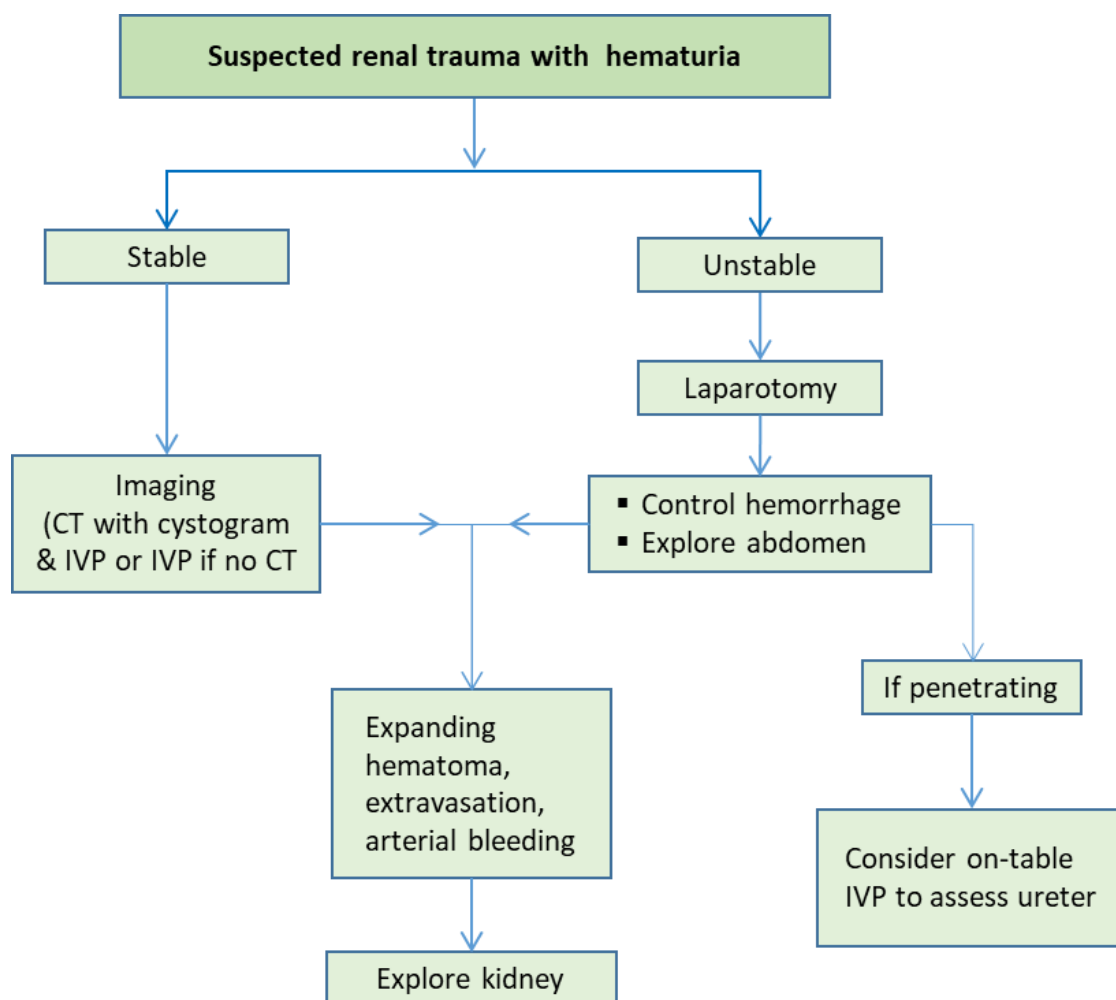
Figure 1. Algorithm for Urologic Trauma



RENAL TRAUMA

Patients with penetrating renal injuries often have associated injuries to other intra-abdominal organs that require laparotomy. Evidence based guidance on direct evaluation of the kidney for high velocity penetrating trauma during laparotomy is lacking. Generally, a hematoma confined to the retroperitoneum is left undisturbed; persistent bleeding and expanding or medial hematomas suggesting a hilar, aortic, or caval injury warrant direct evaluation.¹¹ The decision as to repair or remove the damaged kidney at that time depends on the salvage-ability of the kidney and the ability of the patient to tolerate the procedure. High velocity kidney injuries are difficult to reconstruct and often result in nephrectomy. (See [Nephrectomy](#) in [Appendix A: Urological Diagnosis and Treatments](#).)¹² Ureteral injuries are nearly always secondary to penetrating trauma and a high index of suspicion based upon suspected bullet or fragment trajectory is necessary to avoid missing the diagnosis; IVP can be helpful if it can be performed in the operating room.^{13,14} Hematuria may be absent and the only clue may be injuries to organs close to the path of the ureter or an unexplained rise in serum creatinine. (See [Appendix A: Urological Diagnosis and Treatments](#).)¹⁴ An algorithmic approach to renal trauma management is presented in Figure 2 below.

Figure 2. Renal Trauma Algorithm



BLADDER TRAUMA

Bladder injuries may be secondary to blunt or penetrating trauma. Bladder rupture from blunt trauma is typically associated with pelvic fracture and results in gross hematuria. Thus, the combination of these two findings (hematuria + pelvic fracture) warrants retrograde plain film or CT cystography to evaluate for bladder injury.¹¹ Penetrating bladder injury must be excluded when the trajectory of the penetrating object is near the pelvis or lower abdomen.¹⁵ Retrograde (plain film or CT) cystography should be performed prior to exploratory laparotomy if possible. However, when imaging is not possible prior to abdominal exploration, large intraperitoneal bladder injuries can be rapidly excluded by filling the bladder in a retrograde fashion with 200-300 ml of sterile saline or dilute methylene blue via the Foley catheter and inspecting for leakage of the fluid into the peritoneal cavity. Extraperitoneal injuries cannot be reliably excluded using this technique.

Extraperitoneal injuries may benefit from immediate repair when pelvic fractures result in exposed bone spicules in the bladder lumen, concurrent rectal or vaginal lacerations may lead to fistula formation to the ruptured bladder, for bladder neck injuries that may not heal with catheter drainage alone, or when the patient is undergoing open repair of concurrent abdominal pelvic injuries in the stable patient.¹¹ Bladder injury from penetrating trauma will often have an entrance and exit wound and have a high incidence of concurrent rectal injury.¹⁵ While intraperitoneal bladder rupture **must** be repaired, extraperitoneal rupture can be managed non operatively with Foley catheter drainage. Bladder repair is performed using a 2 layer closure with absorbable sutures and bladder catheter drainage. (See [Bladder Injuries](#) in Appendix A: Urological Diagnosis and Treatments.) Bladder injury from penetrating trauma has a high incidence of concurrent rectal injury.¹⁵

URETHRAL TRAUMA

Urethral injuries are identified by retrograde urethrography. Blunt anterior urethral injuries should be stented with a urethral catheter when possible or diverted with a suprapubic cystostomy.¹¹ Posterior urethral injuries, however, can be managed with suprapubic cystostomy alone.¹¹ A judicious attempt to realign the urethra endoscopically can be performed at subsequent operative evaluations when the patient is clinically stable several days following injury.¹¹ Penetrating anterior urethral injuries can be primarily repaired with fine absorbable suture over a urethral catheter when the degree of soft tissue injury/contamination is limited. However, when complex blast injury results in anterior urethral injury associated with significant soft tissue loss of the perineum and/or genitalia, urinary diversion alone (transurethral or suprapubic) is sufficient to facilitate urinary drainage until the patient can be evaluated by a urologist who can assist with the wound care and complex urethrogenital reconstruction frequently needed in these cases.

EXTERNAL GENITALIA

With the rise in dismounted complex battle injuries from explosive devices in current combat operations and polytrauma involvement of the lower extremities, perineum, pelvis, and lower abdomen; greater attention has turned to the management of soft tissue injury to the external genitalia and urethra. Initial operative management involves a thorough assessment of the injury sites with removal of wound contaminants and debridement of non-viable tissue. This is done in conjunction with copious, low-pressure irrigation of the wound.³ Testicular injuries are easily missed due to small scrotal entry wounds in some cases and require a high index of suspicion when evaluating patients with significant blast injury. (See [External Genitalia Injuries](#) in [Appendix A: Urological Diagnosis and Treatments](#).) It is imperative to preserve all viable tissue when addressing injuries to the external genitalia to improve functional outcomes on recovery.¹⁶

In addition to arterial bleeding, vascular structures of the penis and scrotum should be addressed on initial surgery, specifically, the corpora cavernosa, corpus spongiosum, and bilateral testes. Lacerations to the corpora

cavernosa can be closed with absorbable suture taking care to avoid the dorsal neurovascular structures. Aggressive over sewing of the corpus spongiosum, however, should also be avoided in favor of site specific closure to its tunical covering reducing risk of ischemic changes distal to the injury site in these complex wounds.¹⁷ Patients with penetrating scrotal wounds or evidence of testicular rupture on exam should undergo scrotal exploration. Ruptured testes are managed with irrigation and debridement of non-viable seminiferous tubules. The tunica albuginea is then closed and returned to the scrotum.¹¹ A tunica vaginalis flap can be used to close the defect when there is insufficient tunica to obtain a tension free closure over the exposed tubules.¹⁸ A delay in managing a testicular injury is acceptable when the patient is too unstable or there is insufficient expertise to manage it at initial exploration. Every attempt should be made to salvage viable testicular tissue especially when both testicles are involved or a unilateral orchiectomy is required. The injured testis should be wrapped in saline soaked gauze and protected with multiple layers of additional dressing. A vacuum assisted dressing is not appropriate if the tunica is left open. These findings should be communicated to the next echelon of care.

The superficial fascia and skin layers of the penis can and should be left open following high energy trauma. Loose approximation of these layers with interrupted suture allows continued tissue evaluation and additional wound debridement. A moist gauze or negative pressure dressing is appropriate. Alternatively, Penrose drains can be placed between loosely approximated interrupted sutures. In cases where scrotal closure is impossible, the testis can be covered with a non-adherent dressing followed by a negative pressure dressing. Creation of a sub dermal thigh pouch is rarely necessary during early surgical care.

With the recent introduction of female combatants to all roles in the military, we anticipate a new constellation of injuries not previously encountered. These will include labial, clitoral, and vaginal soft tissue injuries. Currently there is limited evidence-based direction in the management of these injuries. Initial care should focus on good exposure of the injured tissue with a complete examination to include the vaginal vault, urethra, and meatus with low pressure irrigation and judicious debridement of devascularized tissue. Limited debridement should be practiced around the clitoris favoring repeat examinations in the operating room with intervention as needed. This new injury pattern will need to be prospectively tracked to ensure appropriate care.

PERFORMANCE IMPROVEMENT (PI) MONITORING

INTENT (EXPECTED OUTCOMES)

- Appropriate imaging was obtained in hemodynamically stable patients.
- Retrograde urethrography is performed in patients with suspected urethral injury or blood at the meatus.
- Retrograde cystography is performed in patients with gross hematuria who have a mechanism of injury concerning for bladder injury, pelvic ring fracture, or findings on physical exam or imaging concerning for bladder rupture.
- Intravenous (IV) contrast enhanced computed tomography (CT) with delayed imaging is performed in stable blunt trauma patients with gross hematuria or microscopic hematuria and systolic blood pressure < 90mmHG, or in any stable trauma patients with mechanism of injury or physical exam findings concerning for renal injury (e.g., rapid deceleration, significant blow to flank, rib fracture, significant flank ecchymosis, penetrating injury of abdomen, flank, or lower chest).

PERFORMANCE/ADHERENCE MEASURES

All blunt trauma patients with gross hematuria (regardless of initial SBP) and those patients with microscopic hematuria whose initial SBP is less than 90 mmHg had contrast enhanced CT scan performed (where available) if/when they become hemodynamically stable.

DATA SOURCE

- Patient Record
- Department of Defense Trauma Registry (DoDTR)

SYSTEM REPORTING & FREQUENCY

The above constitutes the minimum criteria for PI monitoring of this CPG. System reporting will be performed annually; additional PI monitoring and system reporting may be performed as needed.

The system review and data analysis will be performed by the Joint Theater Trauma System (JTS) Director and the Performance Improvement Branch.

RESPONSIBILITIES

It is the trauma team leader's responsibility to ensure familiarity, appropriate compliance and PI monitoring at the local level with this CPG.

REFERENCES

1. Dismounted Complex Blast Injury Task Force, Dismounted Complex Blast Injury Report of the Army, 18 Jun 2011. <http://www.dtic.mil/dtic/tr/fulltext/u2/a550676.pdf> Accessed Mar 2018.
2. Emergency War Surgery Handbook, 4th United States Revision 2013. Borden Institute. Walter Reed Army Medical Center, Washington, D.C. Chapter 18: Genitourinary Tract Injuries. 2013: 288
3. Joint Trauma System, Management of War Wounds: Debridement and Irrigation. CPG, 25 Apr 2012. [http://jts.amedd.army.mil/assets/docs/cpgs/JTS_Clinical_Practice_Guidelines_\(CPGs\)/War_Wounds_Debridement_Irrigation_25_Apr_12_ID31.pdf](http://jts.amedd.army.mil/assets/docs/cpgs/JTS_Clinical_Practice_Guidelines_(CPGs)/War_Wounds_Debridement_Irrigation_25_Apr_12_ID31.pdf) Accessed Mar 2018.
4. Combat Urologic Trauma in US Military Overseas Contingency Operations. F Serkin, D Soderdahl, J Hernandez, M Patterson, L Blackbourne, C Wade. J Trauma 69: S175-178, 2010.
5. Battlefield Urologic Injuries: The Gulf War Experience. I Thompson, S Flaherty, A Morey. J Am Coll Surg. 187: 139-141, 1998.
6. Operative Management of Wartime Genitourinary Injuries at Balad Air Force Theater Hospital, 2005 to 2008. S Hudak, S Hakim. J Urol. 182: 180-183, 2009.
7. Battlefield Urogenital Injuries: Changing Patterns during the Past Century. S Hudak, A Morey, T Rozanski, C Fox. Urology 65: 1041-1046, 2005.
8. Genitourinary Trauma at a Combat Support Hospital during Operation Iraqi Freedom: The Impact of Body Armor, E Paquette. J Urol. 177: 2196-2199, 2007.
9. Improvised explosive device-related lower genitourinary trauma in current overseas combat operations. Banti M, Walter J, Hudak S, Soderdahl D. J Trauma Acute Care Surg. 2016 Jan;80(1):131-4
10. Penetrating trauma to the external genitalia in Operation Iraqi Freedom. Waxman S, Beekley A, Morey A, Soderdahl D. Int J Impot Res. 2009 Mar-Apr;21(2):145-8.

11. Urotrauma: AUA guideline. Morey AF , Brandes S , Dugi DD 3rd , Armstrong JH , Breyer BN , Broghammer JA , Erickson BA , Holzbeierlein J , Hudak SJ , Pruitt JH , Reston JT , Santucci RA, Smith TG 3rd , Wessells H; American Urological Association. J Urol. 2014 Aug;192(2):327-35.
12. Review of the Current Management of Upper Urinary Tract Injuries by the EAU Trauma Guidelines Panel. Serafetinides E, Kitrey ND, Djakovic N, Kuehhas FE, Lumen N, Sharma DM, Summerton DJ. Eur Urol. 2015 May 67(5), 930–936
13. Delayed Diagnosis of Traumatic Ureteral Injuries. D Kunkle, B Kansas, A Pathak, A Goldberg, J Mydlo. J Urol. 176: 2503-2507, 2006.
14. Ureteral injuries from external violence: the 25-year experience at San Francisco General Hospital. Elliott SP , McAninch JW. J Urol. 2003 Oct;170(4 Pt 1):1213-6.
15. Gunshot wounds to the lower urinary tract: a single-institution experience. Cinman NM , McAninch JW, Porten SP, Myers JB, Blaschko SD, Bagga HS, Breyer BN. J Trauma Acute Care Surg. 2013 Mar;74(3):725-30
16. Penetrating External Genital Trauma: A 30-Year Single Institution Experience. S Phonsombat, V Master, J McAninch. J Urol. 180: 192-196, 2008.
17. Management of combat-related urological trauma in the modern era. Williams M, Jezior J. Nat Rev Urol. 2013 Sep;10(9):504-12
18. Gunshot wound injury of the testis: the use of tunica vaginalis and polytetrafluoroethylene grafts for reconstruction. Ferguson GG, Brandes SB. J Urol. 2007 Dec;178(6):2462-5.

APPENDIX A: UROLOGICAL DIAGNOSIS AND TREATMENTS

Diagnosis	Treatment
Hematuria	<ul style="list-style-type: none"> Place Foley catheter during trauma assessment unless contra-indicated such as blood at the urethral meatus or other evidence of urethral injury (pelvic fracture). Perform a retrograde urethrogram (RUG) before attempted catheterization when there is concern for a urethral injury. RUG – Obtain an oblique plain film of the pelvis with the patient's bottom leg flexed at the knee and the top leg straight. Severely injured patients or those with suspected spine fractures can be left supine. Alternately, C-arm or fluoroscopy can be used. A 12Fr Foley catheter or catheter tipped syringe is inserted into the fossa navicularis, the penis placed on traction, and 20 mL of undiluted water soluble contrast injected under gentle pressure. Images are obtained. The study is considered normal only if contrast enters the bladder without extravasation. For an anterior urethral injury, plan on repair in the operating room (OR). For a posterior urethral injury, a supra-pubic catheter can be placed in the OR, or percutaneously in the emergency department (ED) for patients who do not need surgery and an appropriate kit is available. For partial urethral disruption by RUG, a single attempt with a well-lubricated catheter may be attempted by an experienced team member in the ED. If the catheter passes, and gross hematuria is noted, proceed with GU diagnostic evaluation for bladder injury or a renal/ureteral source. CT scan with delayed images and CT cystogram are appropriate imaging studies (see technique description following).
Renal Injury	<ul style="list-style-type: none"> Clinicians should perform diagnostic imaging with intravenous (IV) contrast enhanced computed tomography (CT) with delayed imaging in stable blunt trauma patients with gross hematuria or microscopic hematuria and systolic blood pressure < 90mmHG or in any stable trauma patients with mechanism of injury or physical exam findings concerning for renal injury (e.g., rapid deceleration, significant blow to flank, rib fracture, significant flank ecchymosis, penetrating injury of abdomen, flank, or lower chest). Renal Injury Grading <ul style="list-style-type: none"> Grade 1: Sub-capsular hematoma Grade 2: Small parenchymal laceration Grade 3: Deeper parenchymal laceration without entry into collecting system Grade 4: Laceration into collecting system with extravasation; vascular injury with contained hemorrhage Grade 5: Shattered kidney or renal pedicle avulsion Hemodynamically stable patients can be managed without surgical exploration in most cases. Hemodynamically unstable patients with no or transient response to resuscitation should have immediate intervention. Vascular repair is indicated for salvageable kidneys with renal artery or vein injury. Ureteral stenting may be needed for enlarging urinoma or persistent urinary extravasation with fever, pain, ileus, fistula, or infection.
Renal Exploration During Abdominal Operation	<ul style="list-style-type: none"> Stable perirenal hematomas found at time of exploration should not be routinely opened. Renal exploration should be performed at time of laparotomy for persistent bleeding, expanding hematoma, or a central hematoma suggesting a renal hilum injury
Nephrectomy	<ul style="list-style-type: none"> Total nephrectomy is immediately indicated in extensive renal injuries when the patient's life would be threatened by attempted renal repair. A common surgical approach is a lateral to medial mobilization of the kidney to expose the renal pedicle after incision of the peritoneal attachments of the colon to the lateral wall. While there is insufficient data to recommend initial vascular control of the renal pedicle through a mesentery window prior to exploration, this remains an acceptable principle for renal surgery. Damage control by packing the wound to control bleeding and attempting to correct metabolic and coagulation abnormalities, with a plan to return for corrective surgery within 24 hours is an option.

Diagnosis	Treatment
Renal Repair and Partial Nephrectomy Principles	<ul style="list-style-type: none"> • Non-surgical management can result in renal preservation even with high grade injuries. Renal repair is appropriate after gaining hemorrhage control and hemodynamic stability for potentially salvageable kidneys identified during exploration. • Technique: Complete renal exposure, debridement of nonviable tissue, hemostasis by individual suture ligation of bleeding vessels, watertight closure (absorbable suture), drainage of the collecting system, and coverage/approximation of the parenchymal defect. • Perform partial nephrectomy if reconstruction is not possible: the collecting system must be closed and the parenchyma covered with fat or omentum. Consider the use of hemostatic agents and tissue sealants if available. • Place ureteral stent for persistent urinary extravasation.
Ureteral Injuries	<ul style="list-style-type: none"> • Identification of ureteral injury requires a high index of suspicion. It should be evaluated with IV contrast enhanced CT with delayed imaging or direct inspection during laparotomy if preoperative imaging is not available. • Ureteral contusions can be managed by stenting or judicious excision of the injured area with primary anastomosis depending on its severity. Simple ureteral lacerations should be closed primarily. • Complete transections of the ureter proximal to the iliac vessels can be repaired using a tension free, end to end, spatulated anastomosis over a ureteral stent. Transections distal to the vessels should be managed with a ureteral reimplantation over a stent. A psoas hitch or Boari flap may be necessary in some cases. • In cases of inadequate ureteral length to re-anastomose or hemodynamic instability of the patient intraoperatively, a pediatric feeding tube or open ended ureteral catheter may be placed in the proximal ureter and brought out through the skin and placed to closed drainage. Reconstruction of the ureter can then be performed at a future date. • An ureteropelvic junction (UPJ) avulsion injury should undergo re-anastomosis of the ureter to the renal pelvis over a stent. • A drain should be considered after ureteral repair.
Bladder Injuries	<ul style="list-style-type: none"> • Perform retrograde cystography in patients with gross hematuria and a mechanism concerning for bladder injury, finding on exam or imaging concerning for bladder rupture, or pelvic ring fracture. • Retrograde cystography can be done by CT or plain film. For CT cystogram use diluted Conray to reduce scatter artifact from the contrast. A minimum of 300 ml is needed for an adequately study. Plain film images should include a scout film and an AP image with or without oblique views both with the bladder full and again after it is drained. • Extraperitoneal extravasation of contrast can be managed with Foley catheterization alone in most cases. Open repair is indicated for complicated ruptures that include pelvic fractures with exposed bone spicules in the bladder and concurrent rectal or vaginal lacerations that may lead to fistula formation. Patient's undergoing exploration for other indications that are appropriately stable and those with significant bladder neck involvement should be considered for closure. A transvesical approach can reduce disruption of the pelvic hematoma. • Intraperitoneal rupture requires open repair, two-layer closure with absorbable suture, and perivesical drain placement. A large caliber urethral catheter without suprapubic catheter is usually sufficient for bladder drainage. Patients with complex lower extremity, pelvic, or perineal injuries and those requiring prolonged immobilization may benefit from suprapubic catheter drainage as well. • Follow up cystography should be performed prior to catheter removal

Diagnosis	Treatment
Urethral Injuries	<ul style="list-style-type: none"> • Diagnosis: A RUG should be performed in any case of suspected urethral injury. For partial urethral tears, a single attempt at urethral catheterization with a well lubricated catheter may be attempted by an experienced provider. • Anterior urethral injuries: Primary repair of uncomplicated penetrating injury to the anterior urethra may be performed using fine absorbable sutures with careful mucosal to mucosal apposition over a urethral catheter. Immediate repair should not be performed in the setting of extensive tissue damage or urethral loss, patient instability, or surgeon inexperience. Bleeding from the corpus spongiosum can be controlled with site specific fine absorbable suture. Bladder drainage should be established by urethral catheterization or suprapubic drainage. • Posterior urethral injuries: These injuries are typically associated with pelvic fractures or deep penetrating trauma. Suprapubic urinary drainage with delayed reconstruction is the accepted treatment for the majority of cases. Endoscopic alignment may be attempted within the first several days after injury in a hemodynamically stable patient. Aggressive attempts at realignment should be avoided.
External Genitalia Injuries	<ul style="list-style-type: none"> • The primary goals in the management of genital injuries are hemorrhage control and tissue preservation. • Hemorrhage can occur from small arteries on the dorsal penile shaft and/or the spermatic cord. These vessels can be managed with precise cautery. • Large volume, low pressure, irrigation with normal saline should be performed with each surgical intervention. Delayed wound closure is appropriate for significant injuries with considerable tissue damage. Negative pressure wound dressings are well tolerated but often require creative placement techniques when applied to the genitalia. A non-adherent silicone or hydrophilic white foam dressing can be used to cover exposed testicles or freshly repaired corporal tissue when using a negative pressure dressing. • Penile injury may include the corpus spongiosum or corpus cavernosa, and can result in continued hemorrhage. These can be repaired by approximation of the tunical margins with absorbable sutures in a hemostatic fashion following irrigation and debridement of necrotic or devitalized tissue. • The glans is well vascularized and can generally be closed with interrupted absorbable suture. • Scrotal injuries are managed in a similar fashion as other soft tissue wounds. Small penetrating injuries can result in significant testicular damage. There should be a low threshold for surgical exploration in these cases. The scrotum should undergo irrigation and debridement with primary or delayed closure. Widely spaced absorbable suture and a Penrose drain can be used in lieu of a negative pressure dressing when delayed closure is required. • Testicle injuries can be diagnosed with physical exam or scrotal ultrasound. CT or sonography may also show evidence of foreign bodies or air in the scrotum or abnormality of one or both testes. Equivocal cases should be explored. Necrotic testicular tissue should be debrided and the capsule closed with absorbable suture. A tunical vaginalis flap can be used when the tunica albuginea is deficient for closure.

APPENDIX B: ADDITIONAL INFORMATION REGARDING OFF-LABEL USES IN CPGS

PURPOSE

The purpose of this Appendix is to ensure an understanding of DoD policy and practice regarding inclusion in CPGs of “off-label” uses of U.S. Food and Drug Administration (FDA)–approved products. This applies to off-label uses with patients who are armed forces members.

BACKGROUND

Unapproved (i.e., “off-label”) uses of FDA-approved products are extremely common in American medicine and are usually not subject to any special regulations. However, under Federal law, in some circumstances, unapproved uses of approved drugs are subject to FDA regulations governing “investigational new drugs.” These circumstances include such uses as part of clinical trials, and in the military context, command required, unapproved uses. Some command requested unapproved uses may also be subject to special regulations.

ADDITIONAL INFORMATION REGARDING OFF-LABEL USES IN CPGS

The inclusion in CPGs of off-label uses is not a clinical trial, nor is it a command request or requirement. Further, it does not imply that the Military Health System requires that use by DoD health care practitioners or considers it to be the “standard of care.” Rather, the inclusion in CPGs of off-label uses is to inform the clinical judgment of the responsible health care practitioner by providing information regarding potential risks and benefits of treatment alternatives. The decision is for the clinical judgment of the responsible health care practitioner within the practitioner-patient relationship.

ADDITIONAL PROCEDURES**Balanced Discussion**

Consistent with this purpose, CPG discussions of off-label uses specifically state that they are uses not approved by the FDA. Further, such discussions are balanced in the presentation of appropriate clinical study data, including any such data that suggest caution in the use of the product and specifically including any FDA-issued warnings.

Quality Assurance Monitoring

With respect to such off-label uses, DoD procedure is to maintain a regular system of quality assurance monitoring of outcomes and known potential adverse events. For this reason, the importance of accurate clinical records is underscored.

Information to Patients

Good clinical practice includes the provision of appropriate information to patients. Each CPG discussing an unusual off-label use will address the issue of information to patients. When practicable, consideration will be given to including in an appendix an appropriate information sheet for distribution to patients, whether before or after use of the product. Information to patients should address in plain language: a) that the use is not approved by the FDA; b) the reasons why a DoD health care practitioner would decide to use the product for this purpose; and c) the potential risks associated with such use.